

Original article

Patterns of direct immunofluorescence in sub-epidermal autoimmune bullous diseases of skin in Lahore, Pakistan

Tariq Mahmood, Tahir Saeed Haroon

Department of Dermatology, King Edward Medical College, Lahore

Abstract *Background* Autoimmune subepidermal blistering diseases are common in dermatological practice. Direct immunofluorescence study is considered gold standard for the diagnosis of this group.

Objective This study was conducted to determine the patterns of direct immunofluorescence in subepidermal autoimmune bullous diseases of skin in Lahore, Pakistan.

Patients and methods During a period of 6 months, 26 (14 males and 12 females) patients of subepidermal autoimmune bullous diseases were recorded. Histopathology and direct immunofluorescence were performed in all of these patients.

Results Immunostaining at the dermo-epidermal junction was seen in all cases. The patterns on DIF in different diseases were: bullous pemphigoid (n=14) linear deposits of IgG (100%) and C3 (71.4%); dermatitis herpetiformis (n=4), granular deposits of only IgA (100%); linear IgA disease (n=5), linear deposit of IgA (100%) and C3 (20%); pemphigoid gestationis (n=2), linear deposits of IgG (100%) and C3 (100%); and bullous lupus erythematosus (n=1), linear deposit of IgG, IgA and IgM (100% each). No case of cicatricial pemphigoid or epidermolysis bullosa acquisita was seen.

Conclusion DIF patterns in most of them especially in LAD and DH, were very specific, but in others clinical help was necessary to reach at the exact diagnosis as in pemphigoid gestationis and bullous LE.

Key words Direct immunofluorescence, autoimmune, subepidermal, bullous diseases, Lahore.

Introduction

Autoimmune blistering diseases are a group of bullous disorders characterized by pathogenic antibodies directed at the target antigens which are components of desmosomes or the adhesion complex at dermo-epidermal junction (DEJ). They are divided into epidermal and subepidermal groups depending upon the level of split.

Subepidermal group is further divided into various subtypes including bullous pemphigoid (BP), cicatricial pemphigoid (CP), pemphigoid gestationis (PG), linear IgA disease (LAD), dermatitis herpetiformis (DH), bullous LE (BLE) and epidermolysis bullosa acquisita (EBA).¹

Immunofluorescence has become an indispensable diagnostic tool in the diagnosis of autoimmune bullous diseases. Direct immunofluorescence, in particular,

Address for Correspondence

Dr. Tariq Mahmood,
Dermatology Department,
Mayo Hospital, Lahore.

is important in the diagnosis of subepidermal autoimmune bullous disorders.²

Although, it is not widely available in Pakistan, it is considered the “gold standard” for the diagnosis of autoimmune bullous diseases. This study was planned to establish the patterns of direct immunofluorescence in subepidermal autoimmune bullous diseases (SEABD) in Pakistan and to confirm the clinical diagnosis by direct immunofluorescence (DIF).

Patients and methods

This study was conducted at the Department of Dermatology, Mayo Hospital/King Edward Medical College, Lahore from July, 1999 to December, 1999. Fifty consecutive patients, of any age and either sex, with strong clinical suspicion of an autoimmune bullous disease, presenting to the department, were scrutinized for SEABD. Different SEABDs were diagnosed according the criteria described in **Table 1**.

Clinical features, results of laboratory investigations and findings on direct immunofluorescence were recorded on a specially designed proforma. Elliptical biopsy specimens were taken including a fresh lesion and the perilesional skin after local anesthesia.

Lesional biopsy specimens were collected in 10% formalin solution and used for histopathology after standard processing. The sections were stained with hematoxylin and eosin. Histopathological findings were used as a further aid in the diagnosis.

Perilesional skin samples were used for performing direct immunofluorescence. Tissue samples were taken in saline-soaked gauze pieces and then immediately taken to the laboratory. In the laboratory, they were embedded in the cryostat embedding medium. They were snap-frozen and then stored in liquid nitrogen for further processing.³⁻⁵

Table 1

Criteria for diagnosis of various subepidermal autoimmune bullous diseases in the study [9]

Diagnosis	Clinical	Direct immunofluorescence
BP	Bullae/vesicles/erosions/urticarial rash; absence of scarring	Linear IgG and/or C3 at BMZ
CP	Predominant mucosal lesions; heal with scarring	Linear IgG and/or C3 at BMZ
PG	As for bullous pemphigoid; pregnancy or trophoblastic tumours	Linear IgG and/or C3 at BMZ
LAD	Vesicles/papules/erosions/urticated plaque	Linear IgA at BMZ
DH	Vesicles/papules/erosions/weals	Granular IgA in dermal papillae
EBA	Trauma-induced bullae/vesicles/erosions; heal with scarring	Linear IgG and/or C3 at BMZ
Bullous LE	Bullae/vesicles/erosions; heal with scarring; positive ARA criteria	Linear IgG and/or C3 at BMZ

ARA, American rheumatism association; BMZ, Basement membrane zone; BP, bullous pemphigoid; CP, cicatricial pemphigoid; DH, dermatitis herpetiformis; EBA, epidermolysis bullosa acquisita; LAD, Linear IgA disease; LE, Lupus erythematosus; PG, pemphigoid gestationis

Table 2
Frequency of different immunoreactants in various SEABDs

Disease	IgG	IgA	IgM	C3	Fibrin
BP (n=14)	100%	7.1%	28.6%	71.4%	-
LAD (n=5)	20%	100%	-	20%	-
DH (n=4)	100%	-	-	-	-
PG (n=2)	100%	-	-	100%	-
Bullous LE (n=1)	100%	100%	100%	-	-

BP, bullous pemphigoid; DH, dermatitis herpetiformis; LAD, linear IgA disease; LE, lupus erythematosus; PG, pemphigoid gestationis

For sectioning, a block of the tissue was made in embedding medium on a metal chunk and then 5 micrometer-thick sections were cut in the cryostat at -30°C . Six sections of each specimen were taken on standard glass slides and air dried for 10 minutes. For DIF staining of the biopsy sections, slides along with positive and negative controls were rinsed in phosphate buffered saline.^{4,5}

The sections were treated with fluorescein isothiocyanate (FITC)-labeled, optimally diluted antisera i.e. IgG, IgA, IgM, C₃ and fibrinogen. The negative control slides were not treated so. They were then incubated in a moist, closed, plastic container at room temperature for 20 minutes. The unreacted antiserum was washed off the sections by dipping the slides sequentially into three jars of phosphate buffer solution. These were allowed to drain and excess buffer was wiped from the bottom of the slide and around the section with dry cotton gauze. The slides were mounted using a drop of buffered glycerin as the mounting medium (90% glycerin in PBS). Finally, sections were examined under a fluorescence ultraviolet microscope for their

immunofluorescence patterns.^{4,5} The results were obtained by recording these details on a specially designed proforma.

Results

Of 50 enrolled patients, 6 (52%) belonged to the subepidermal group. There were 14 (53.9%) male and 12 (46.1%) female patients. The age ranged from 1-80 years. The youngest patient belonged to the childhood subtype of linear IgA disease and the oldest patient was that of bullous pemphigoid. **Table 2** enlists the frequency of different immunoreactants in various disease entities.

Out of 26 patients with subepidermal blistering, 14 (53.9%) patients were suffering from bullous pemphigoid. A continuous, thin, linear fluorescence was observed at the dermo-epidermal junction in all patients (**Figure 1**). IgG was seen in all of them while C3 was also observed in 10 (71.4%) patients. IgM was deposited in 4 (28.6%) patients and in one (7.1%) patient mild fluorescence with IgA was seen in a similar pattern.

Five (19.3%) patients had linear IgA disease, 2 were of adult LAD and 3 with childhood variant. **Figure 2** shows the




Figure 1 Linear IgG deposits at dermo-epidermal junction in BP

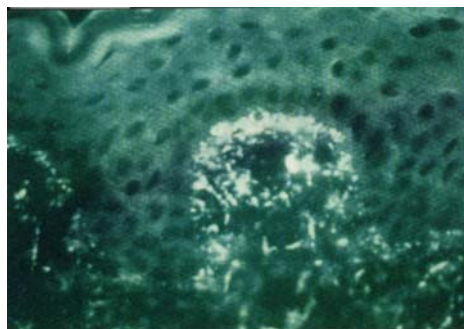


Figure 3 Granular IgA deposits at papillary tips in DH

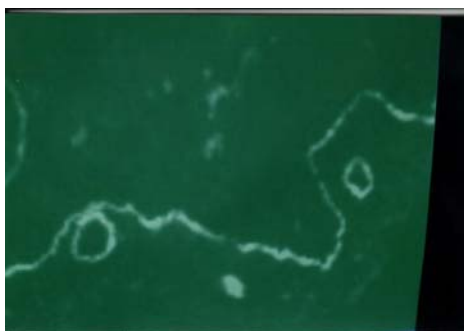

Figure 2 Linear IgA deposits at dermo-epidermal junction in LAD



Figure 4 Linear IgM deposits at dermo-epidermal junction in bullous LE

fluorescence as a continuous, linear homogeneous pattern at the DEJ. In all five patients IgA was the predominant immunoreactant. In one patient with adult linear IgA disease, mild fluorescence was also observed with IgG and in another with CBDC, C3 deposition was seen. Dermatitis herpetiformis and bullous pemphigoid was suspected in one case each. Both turned out to be linear IgA disease.

Diagnosis of DH was made in 4 (15.4%) patients. All of them demonstrated granular deposits of IgA exclusively in the dermal papillae (**Figure 3**). No other immunoreactant including IgM, IgG or C3 was detected.

Two (7.7%) female patients were diagnosed as pemphigoid gestationis. Both of them had deposition of C3 and IgG at the dermo-epidermal junction in a thin, continuous, linear pattern. Fluorescence

with C3 was more prominent than that of IgG.

Solitary (3.7%) patient with bullous LE showed linear thin pemphigoid-like homogeneous fluorescent band of IgG, IgA and IgM at DEJ (**Figure 4**).

Discussion

In the present study, bullous pemphigoid was the most common subepidermal disease diagnosed in 14 (53.9%) of total 26 patients. BP has been reported to be the most common SEABD in studies from different countries.⁶⁻⁹ Fluorescence was seen in a thin, linear and continuous pattern at the DEJ. IgG was observed in 100% of patients and C3 in 10 (71.4%) patients. Generally, patterns were the same as seen in other studies.¹⁰ Average age at presentation was 60 years in bullous pemphigoid patients, while one patient that belonged to juvenile pemphigoid group was 11 years old. Same age groups are reported to be commonly involved.^{1,10}

Out of five patients with linear IgA disease, 3 belonged to the CBDC type and 2 were those of adult linear IgA disease. IgA was demonstrated in a linear and continuous pattern at the dermo-epidermal junction, which is the usual pattern seen in these patients.¹¹⁻¹³ In one patient, IgM and C3 were also seen in addition, in a similar pattern.

Four patients with subepidermal disease were diagnosed as suffering from dermatitis herpetiformis, with the established pattern of granular IgA at the papillary tips.^{1,12,13}

Two patients of pemphigoid gestationis were differentiated clinically from bullous pemphigoid, as the direct immunofluorescence patterns were exactly similar in both conditions, except that deposition of C3 was more common in pemphigoid gestationis than IgG.^{1,10}

One patient diagnosed as bullous LE, fulfilled the American Rheumatism Association (ARA) criteria for SLE. DIF pattern in bullous LE mimics that of BP, CP and EBA. BP can be differentiated by immunofluorescence studies on salt-split specimen, however EBA gives rise to identical pattern and it is the clinical data which differentiates between the two.

In three patients, DIF revealed a different autoimmune bullous disease than what was clinically suspected. Two patients having a clinical diagnosis of DH, and inconclusive histopathology, and one with bullous pemphigoid were diagnosed as linear IgA disease on DIF.

We conclude that most of the autoimmune blistering diseases have specific direct immunofluorescence patterns for diagnosis but sometimes additional information may be required to differentiate them. Direct immunofluorescence is a sensitive diagnostic tool for the diagnosis of autoimmune blistering diseases.

References

1. Wojnarowska F, Eady RA, Burge SM. Bullous eruptions. In: Champion RH, Burton JL, Burns DA, Breathnach SM, eds. *Rook/Wilkinson/Ebling Textbook of Dermatology*. 6th edn. Oxford: Blackwell Science; 1998. p. 1817-98.
2. Mustasim DF, Pelc NJ, Supapannachart N. Established methods in the investigation of bullous diseases. *Dermatol Clin* 1993; **11**: 399-418.
3. Ueki H, Yaoita H. *A Color Atlas of Dermato-immunohistocytology*. 1st edn. Tokyo: Wolfe Medical Publications; 1989. p. 1-12.
4. Vassileva S. Immunofluorescence in dermatology. *Int J Dermatol* 1993; **32**: 153-61.
5. Kamarashev J. Immunohistochemical techniques for light microscopy. In: Kanitakis J, Vassileva S, Woodly D, eds. *Diagnostic immunohistochemistry of the skin*. 1st edn. London: Chapman and Hall Medical; 1998. p. 79-83.
6. Jin P, Shao C, Ye G. Chronic bullous dermatoses in China. *Int J Dermatol* 1993; **32**: 89-92.
7. Bernard P, Vaillant L, Labeille B *et al*. Incidence and distribution of subepidermal autoimmune bullous skin diseases in three French regions. *Arch Dermatol* 1995; **131**: 48-53.
8. Zillekens D, Wever S, Roth A *et al*. Incidence of autoimmune subepidermal blistering dermatoses in a region of Central Germany. *Arch Dermatol* 1995; **131**: 957-8.
9. Wong SN, Chua SH. Spectrum of subepidermal immunobullous disorders seen at National Skin Centre, Singapore: a 2-year review. *Br J Dermatol* 2002; **147**: 476-80.
10. Korman NJ. Bullous pemphigoid. *Dermatol Clin* 1993; **11**: 483-98.
11. Paige DG, Leonard JN, Wojnarowska F, Fry L. Linear IgA disease and ulcerative colitis. *Br J Dermatol* 1997; **136**: 779-82.
12. Collier PM, Kelly SE, Wojnarowska F. Linear IgA disease and pregnancy. *J Am Acad Dermatol* 1994; **30**: 407-11.
13. Banfield CC, Allen J, Wojnarowska FT. Dermatitis herpetiformis and linear IgA disease. In: Kanitakis J, Vassileva S, Woodley D, eds. *Diagnostic Immunohistochemistry of the skin*. 1st edn. London: Chapman and Hall Medical; 1998. p. 105-13.

