

Original article

# Microsclerotherapy as a modality of treatment in superficial venous malformations

Farid Ahmad Khan, \*Khalil Al Nakib, \*Abdul Rehman Awf Quaba

Plastic surgery department, King Edward Medical College/Mayo Hospital, Lahore

\* Laser Suite, Department of Plastic Surgery, St. John's Hospital, Livingston, U.K.

**Abstract** Venous malformation is a difficult clinical problem with a wide spectrum. There is a continuum of localized venous malformations from blue telangiectatic capillaries through spongy blebs, through cavernous lesions to diffuse venous ectasias. Apart from cosmetic concern majority of localized superficial venous malformations are asymptomatic and managed by explanation and reassurance. With the advent of laser therapy patients with this distinct group of superficial flat venous malformations were referred to our laser suite. Response to laser therapy was poor because of large diameter of the abnormal vessels. Microsclerotherapy, an established method of treatment of lower limb telangiectasias, was tried on twenty five patients with localized superficial malformations. The outcome was satisfactory indicating that microsclerotherapy can be used safely as an effective modality of treatment for superficial malformations.

**Key words** Microsclerotherapy, venous malformation.

## Introduction

Venous malformation is the most common vascular malformation.<sup>1</sup> Various modalities of treatment ranging from compression therapy, laser, sclerotherapy and excision have been described in the literature depending upon depth, extent, and symptomatology of the lesion. We present microsclerotherapy as a method of treatment for superficial venous malformations as an alternative to laser treatment which may not be effective because of the depth and relatively large calibre of the vessels.

## Patients and methods

Twenty five patients were selected having distinctive variety of superficial venous

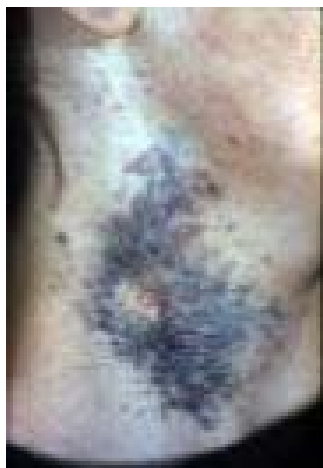malformations with predominantly dermal vessels of 1-3 mm diameter and having no significant underlying "varicose" component. These patients were treated with microsclerotherapy as these were not amenable to laser therapy.

Multiple sessions of microsclerotherapy using 25-30% hypertonic sodium chloride solution were given with the help of 2.0-2.5 ml. disposable syringes. Half inch 30 gauge needles which are 0.3 mm in external diameter, were used for the injections. Magnification (surgical loupes 3.5x) was used for accurate placement of needle in the vein. The amount of injected substance depended upon size and blanching of that particular vein. Multiple sessions of treatment were usually required at six weekly intervals to achieve significant clearance of the venous malformation.<sup>2</sup>

---

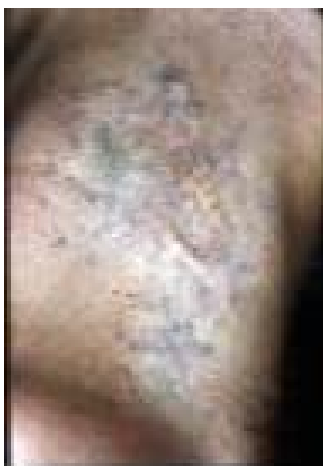### Address for Correspondence

Dr. Farid Ahmad Khan,  
Consultant Plastic Surgeon, Surgimed Hospital,  
1 Zafar Ali Road, Gulberg V, Lahore.



**Figure 1** A 12-year-old girl presented with a superficial venous malformation of right side of her neck

## Results



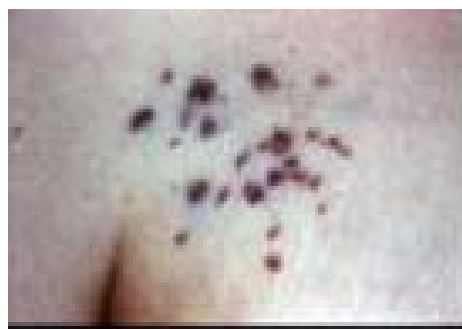**Figure 2** Results after multiple sessions of microsclerotherapy. Hypopigmented area of CO<sub>2</sub> laser test patch has been excised

Microsclerotherapy was tried in twenty five cases which resulted in significant fading of malformation. It was not associated with any adverse skin change during the follow up period of six months to six years in twenty one cases while four patients were lost to follow up.

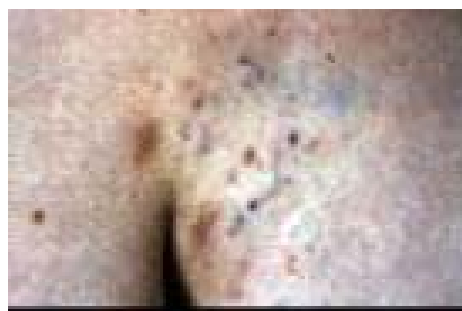
Few cases have been described as follows

### Case 1

A 12-year-old girl was referred with biopsy proven venous malformation on the



**Figure 3** A 9-year-old boy with superficial venous malformation of left anterior axillary fold.



**Figure 4** Two years after treatment with five sessions of microsclerotherapy

right side of her neck (**Figure 1**). Two test patches with different types of laser were tried, one with pulsed dye laser, PDL, (7.5 J/cm<sup>2</sup>, 5mm spot size), with no response, the other test patch was tried with ultrapulsed CO<sub>2</sub> (300 mJ/cm<sup>2</sup>). There was hypopigmentation and textural change noted with the latter patch. Microsclerotherapy was tried for her superficial venous malformation. Five sessions of microsclerotherapy were given. The hypopigmented scar was surgically revised. She responded well and the lesion faded out considerably with no side effects after two years of follow up (**Figure 2**).

### Case 2

A 9-year-old boy was referred to Laser Unit in St. John's Hospital, Livingston, who had superficial venous malformation of left anterior axillary fold (**Figure 3**). Pulsed tunable dye laser (7mm spot size, 7.5 J/cm<sup>2</sup>) was given but it did not respond. Multiple sessions of

microsclerotherapy were given and the outcome was satisfactory as shown in **Figure 4**.

### **Case 3**

Microsclerotherapy was tried in a twenty six year old lady with a superficial vascular malformation involving the lateral aspect of left buttock extending onto the adjacent trochanteric area where two previous excisions were attempted resulting in extensive scarring. Microsclerotherapy resulted in significant reduction of the malformation.

### **Discussion**

Venous malformations are the most common vascular anomalies with propensity for the head and neck.<sup>1</sup> Management of venous malformations depends upon depth, size, signs, symptoms and extent of the lesion. Treatment ranges from masterly inactivity to elastic support therapy, laser, sclerotherapy and excision.<sup>1-4</sup> Selective laser treatment is not very effective in venous malformation because of the relative depth and large calibre of vessels in these malformations. Injections of sclerosing solutions for haemangiomas had its shadowy beginnings in the early nineteenth century with occasional fatal results as described in the case report by Paget in 1837 of a 2 year old child with haemangioma that had been injected with nitric acid and amniotic liquor.

Sclerotherapy refers to the introduction of an irritating solution into the lumen of a vessel causing damage to the endothelial lining and subsequent fibrosis.<sup>4</sup> When it is performed on vessels of diameter 0.3 to 2.0mm, it is referred to as microsclerotherapy.<sup>5</sup> The available

sclerosing agents could be divided into three groups.

The first group comprises of detergent solutions, such as sodium tetradecyl sulphate (STS) and ethanolamine oleate, which cause damage by interfering with cell surface lipids. Strong detergent sclerosants have a low safety margin. Second group comprises of chemical solutions of mild nature such as chromated glycerine. Last group, used in this study, also consists of osmotic agents like hypertonic saline or hypertonic glucose. They produce dehydration of the endothelial cells through osmosis resulting in damage which is proportional to the concentration of the agent.<sup>5</sup>

There is no consensus regarding the type of sclerosing agent and optimal concentration of the solution used. In general, the smaller the diameter of the vessel the lesser the need to use higher concentrations.

Microsclerotherapy is associated with a number of potential complications such as perivascular necrosis, hyperpigmentation,<sup>6</sup> flare of new telangiectasias, mat-like telangiectasias, edema at injection site and localized hirsutism.<sup>8</sup> There are also some serious though rare complications such as systemic allergic reactions, thrombophlebitis and deep venous thrombosis.<sup>1</sup> We used hypertonic saline solution in our patients because of less side effects.<sup>7</sup> Addition of heparin to hypertonic saline provides no benefit but lignocaine 2% could be added to avoid transient pain and muscle cramping experienced in patients undergoing microsclerotherapy with hypertonic saline.<sup>6</sup>

The injection should be under low manual pressure. Use of 2-2.5ml disposable syringes is recommended as higher injection pressure could be generated with insulin syringes leading to extravasation of solution. "Bleb" formation is a sign of perivascular injection. Injection should be stopped and needle withdrawn in such a case. Local anesthetic may be injected into this bleb to dilute the effect of the extravasated sclerosing agent. Correct injection should cause blanching or dilution of colour of the blood vessels in an area of about 1-2 cm around the injection site. Slow injection allows a mild sclerosing agent to stay in contact with the vessel wall for longer period of time and vessel will remain blanched (filled with the sclerosing solution) if the plunger of the syringe is held with zero force while the needle remains motionless.<sup>5</sup>

### **Conclusion**

Microsclerotherapy can be used safely as an effective modality of treatment for superficial venous malformations where no other treatment option is effective.

*This paper was presented in British Association of Aesthetic Plastic Surgery in London and Annual Conference of*

*Dermatology in Faisalabad in 2002 where it won gold medal for the best paper.*

### **References**

1. Berenguer B, Burrows PE, Zurakowski D, Mulliken JB. Sclerotherapy of craniofacial venous malformations: complications and results. *Plast Reconstr Surg* 1999; **104**: 1-9.
2. Georgantopoulou AA, Al-Nakib K, Quaba AA. Treatment of arborising telangiectasia with pulsed tunable dye laser. *Br J Plast Surg* 1999; **51**: 614-20.
3. Quaba AA. Telangiectasia. Is treatment worthwhile and who should pay? In: Ruckley V, ed. *Epidemiology, management and delivery of care for venous disease. 1<sup>st</sup> edn.* London: Springer-Verlag; 1999.
4. Imhoff E, Stemmer R. Classification and mechanism of sclerosing agents. *Soc Franc Phlebol* 1969; **22**: 143-5.
5. Sadik NS. Sclerotherapy of varicose and telangiectatic leg veins: Minimal sclerosing agent concentration of hypertonic saline and its relationship to vessel diameter. *J Dermatol Surg Oncol* 1991; **17**: 65-9.
6. Goldman MP, Kaplan RP, Duffy DM. Postsclerotherapy hyperpigmentation: A histologic evaluation. *J Dermatol Surg Oncol*; **13**: 547-51.
7. Carlin MC, Ratz JL. Treatment of telangiectasia: comparison of sclerosing agents. *J Dermatol Surg Oncol* 1991; **17**: 75-9.
8. Goldman MP, Fitzpatrick RE, eds. *Sclerotherapy as treatment of varicose and telangiectatic leg vein., 1<sup>st</sup> edn.* New York: Mosby; 1995.

