

## Review article

# Immunofluorescence in immunobullous diseases

**Zahida Rani, Ijaz Hussain**

Department of Dermatology, King Edward Medical College/Mayo Hospital, Lahore

**Abstract** Immunofluorescence has become an essential component of today's dermatological laboratory. During the last four decades, innovations in this field have revolutionized the concepts about the pathogenesis, diagnosis and differential diagnosis of autoimmune bullous diseases, hereditary bullous diseases, collagen-vascular diseases, many inflammatory dermatoses and cutaneous tumours. However, the facility is not widely available in Pakistan, and the physicians' knowledge about this diagnostic tool is mostly theoretical. This review envisages the basics of immunofluorescence technique, the interpretation of the results and the newer advancements in the field which a physician is expected to know.

### Introduction

Immunobullous diseases constitute an important group of dermatological disorders caused by pathogenic autoantibodies directed against antigens in the intercellular substance or dermoepidermal junction. These can be further subdivided into intraepidermal and subepidermal.

Intraepidermal immunobullous diseases include the pemphigus group and its variants e.g. pemphigus vulgaris (PV) and pemphigus vegetans, pemphigus foliaceus (PF), endemic pemphigus foliaceus, pemphigus erythematosus (PE), drug-induced pemphigus, IgA pemphigus, and paraneoplastic pemphigus (PNP). Subepidermal immunobullous diseases include bullous pemphigoid (BP), pemphigoid gestationis (PG), cicatricial pemphigoid (CP), linear IgA bullous disease (LABD), epidermolysis bullosa acquisita (EBA), and bullous lupus erythematosus.

Immunofluorescence (IF) is a reliable

biochemical staining technique for the detection of antibodies, which are bound to antigen in the tissue or circulating in body fluids. Since its introduction in dermatology in 1960, it has contributed greatly to the development of concepts and knowledge of bullous and connective tissue diseases, at the same time becoming an indispensable diagnostic tool in routine practice.<sup>1</sup> The relative simplicity and accuracy of the technique has made immunofluorescence an unavoidably powerful technique in the diagnosis of bullous diseases. Even in situations in which the histopathologic findings seem characteristic of a specific bullous disease, IF testing can add to the certainty of diagnosis, sometimes modify it and occasionally reveal a different diagnosis.<sup>2</sup> One of the most reliable characteristics of this technique is the combination of immunological specificity with visual localization.

### History

Immunofluorescence studies are considered the 'gold standard' for the diagnosis of autoimmune blistering

---

#### Address for Correspondence

Dr. Zahida Rani,  
Department of Dermatology,  
Mayo Hospital, Lahore.

diseases. However, it was not before 1941 when Coons *et al.* developed the immunofluorescence techniques for the first time, a discovery which made possible to observe microscopically antigens, antibodies and their related substances on tissue sections or on cell smears.<sup>3</sup> Beutner and Jordon in 1964, made use of this newly introduced technology by demonstrating antibodies in the sera of pemphigus patients reactive to antigens at the periphery of the keratinocytes in the epidermis, by indirect immunofluorescence.<sup>4</sup> Jordon *et al.* performed direct immunofluorescence on lesional and perilesional skin in 1971 to demonstrate the deposition of IgG antibodies at the inter-cellular spaces in the epidermis.<sup>4</sup> Initially, most of the efforts were made in the purification of antisera, search of ideal labeling markers, improvement in cryostat sectioning, better fluorescent microscopy and increasing the sensitivity of microphotography.<sup>3</sup>

During the ensuing years, newer substrates and modified substrate e.g. salt-split specimens used for direct and indirect immunofluorescence to enhance the sensitivity and specificity of the technique. Immunoperoxidase technique, immunoelectron microscopy, immunoprecipitation studies, western blot analysis and enzyme-linked-immunosorbent (ELISA) assays have been developed but IF is still widely practised.

### **Basis of Immunofluorescence**

In immunofluorescence techniques antigens, antibodies or their complexes are viewed under an ultraviolet microscope, using the corresponding antibodies complexed to a fluorochrome. Fluorochromes are the substances that have electrons which, when irradiated with light of certain wavelength, achieve an

unstable higher energetic state. On returning to their basic state, as a spontaneous process, they emit light with a characteristic longer wavelength. The substance initially used by Coons was beta-anthracene, which produces blue fluorescence.<sup>1</sup>

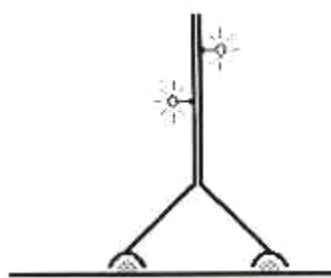
Fluorochromes, currently in use include: fluorescein isothiocyanate (FITC) which produces apple-green color; tetramethylrhodamine isothiocyanate (TRITC) with a red colour of fluorescence; and phycoerythrin, which also shows red fluorescence. These markers are detected with a fluorescence microscope equipped with a mercury-vapor or xenon light source, and appropriate exciter and barrier filters. The exciter filter serves to shed light of necessary wavelength on the examined slide, while the barrier filter stops the exciting photons, letting through only the fluorescent light.<sup>1</sup>

Fluorochromes can be tagged both on polyclonal and monoclonal antibodies as well as on Fab fragments without interfering with the specific binding to antigens.<sup>1</sup>

In order to preserve the specificity of the conjugate, the fluorescein/protein molar ratio should not exceed 4. In the past, every laboratory had to produce its own fluorochrome-labeled antibodies. Nowadays, a wide range of ready-to-use conjugates, suitable for clinical and research work, are available commercially.<sup>1</sup>

### *Types and technique*

The three main variants of the immunofluorescence methods are direct, indirect and complement indirect immunofluorescence.<sup>3</sup>



Legend:

- ⊛ - antigen
- Y - antibody
- ⊛ - fluorochrome

**Figure 1** Direct immunofluorescence

### **1. Direct Immunofluorescence (Patient's Biopsy)**

Direct immunofluorescence (DIF) is a one-step procedure (**Figure 1**).

*Skin biopsy specimen* For DIF, biopsy specimen may be taken with the help of a 3-4 mm punch from perilesional skin or mucosa, a few mm to 1 cm from the edge of lesion. An uninvolved site should be taken to maximize the chances of a positive finding. Mucosal biopsies may be positive, despite the absence of clinical involvement in bullous and cicatricial pemphigoid when the skin is negative.<sup>5</sup> Skin biopsy specimen is either quick frozen or placed in transport medium.

*Quick freezing* The specimen for DIF should be received in fresh state without any fixative. To avoid dehydration, the tissue should be wrapped in saline-moistened gauze. The tissue must be snap-frozen in liquid nitrogen as soon as possible. Several methods are available for snap freezing. The most commonly used method is to place the biopsy in a labeled plastic container i.e. half filled with cryostat embedding compound. The

container is cooled either rapidly in liquid nitrogen or slowly in cryostat (-20°C) until the edges are frozen and central parts remain fluid. The skin specimen is then oriented in the fluid part, covered with more compound and frozen until the consistency of the block is appropriate for cryo-sectioning.<sup>6</sup>

*Transport medium* If for any reasons, the tissue cannot be frozen immediately, it is best stored at 4°C, wrapped in saline-moistened gauze for no longer than 24 hours.<sup>6</sup> Alternatively, acceptable results can be obtained by preserving the biopsy specimens in Michel's transport medium, containing ammonium sulfate that prevents the degradation of tissues. Specimens can be stored in this medium for as long as two weeks.<sup>6</sup> After removal from the fixative, the specimen must be washed three times for ten minutes each time, in the buffer and then subsequently frozen and stored at -70°C until used.<sup>7</sup>

*Sectioning* For sectioning, the metal chunk bearing the frozen tissue specimen is placed in the cryostat. The number of sections to be cut will depend on the number of fluorescent antisera used and additional sections to be used as controls. Sections of 4-6 µm thickness are cut in a cryostat and taken off the cryostat by gently touching with a glass slide. As many as 5-6 sections can be applied on a standard microscopic slide. Tissue sections are separated from each other by straight lines, by wax pencil, to prevent intermixing of fluorescent anti-sera.<sup>6</sup> Alternatively, slides with special chambers to prevent intermixing can be used. The slides are then allowed to air dry for 15 minutes.

*Incubation with FITC-conjugates* After rinsing in a phosphate buffered saline (PBS), slides are overlaid in a moist chamber with FITC-conjugate for 20-30 minutes at 37°C.<sup>7</sup>

As a routine, the following antisera are recommended: anti-IgG, anti-IgA, anti-IgM, anti-C3 and anti-fibrinogen.<sup>6</sup> Other antisera can be used in special circumstances. The unreacted anti-serum is washed off in phosphate buffer solution for 30 minutes (three 10-min changes). The slides are then allowed to drain and the excess buffer is wiped from the bottom of the slide and around the sections with dry cotton gauze. The slides should now be cover-slipped using a drop of buffered glycerin (90% glycerin in PBS) and examined under the fluorescence microscope.<sup>6</sup>

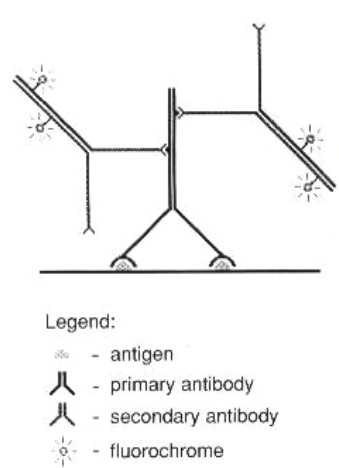
#### *DIF on Salt-Split Specimen*

This technique was developed to differentiate between BP and EBA. Perilesional skin of the patient is processed in 1 M NaCl solution for 24 hours in order to induce a dermal-epidermal separation at the level of lamina lucida and then subjected to the standard DIF procedure.

## **2. Indirect Immunofluorescence (Patient's Serum)**

Indirect immunofluorescence (IIF) is a two-step procedure for demonstrating circulating autoantibodies in a patient's serum (**Figure 2**). It is 10 times more sensitive than DIF.

Patient's blood (5-10 ml) is taken, centrifuged to extract serum after centrifugation. Serial dilutions (1:10, 1:20, 1:40...) are made.



**Figure 2** Indirect immunofluorescence

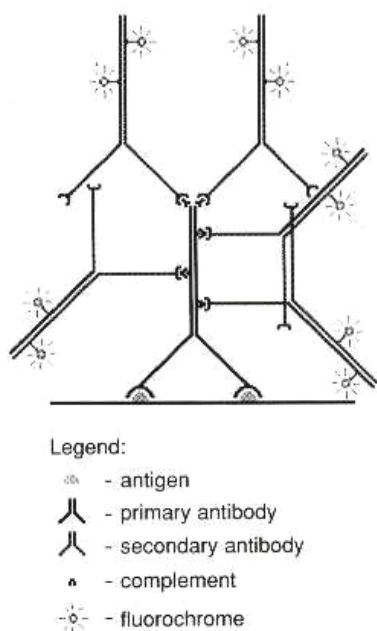
*First Step* This consists of contact between the serum and sections of appropriate substrate, which contains the corresponding antigen. A large number of tissue substrates including monkey esophagus, guinea-pig lip/esophagus, rabbit lip/esophagus, rodent urinary bladder and normal human skin are used.<sup>7</sup> Sections of substrate on glass slides are incubated with (primary unlabelled) patient's serum for 30 minutes. This is followed by three 10-minute washes in PBS.<sup>7</sup>

*Second Step* The second step of IIF is identical to the staining procedure of the DIF technique. Sections are treated with FITC conjugated anti-IgG, IgA, IgM at 37 °C for another 30 minutes. After the final three washes (10 minutes each in PBS), the sections are air-dried, mounted with buffered glycerol and examined with a fluorescence microscope.<sup>10</sup> Positive (pemphigus and pemphigoid serum) and negative (normal human serum) are incubated in similar fashion.

#### *IIF on Salt-Split Substrate*

The selected substrate is incubated with 1 M NaCl solution for 72 hours to create an

artificial cleavage at the level of lamina lucida and then processed as for routine



**Figure 3** Complement indirect immunofluorescence

IIF. This is also used to differentiate BP and EBA.

### 3. Complement Indirect Immunofluorescence (Patient's serum) [2,3]

This is a very sensitive, three-step serologic technique (**Figure 3**), even more sensitive than routine IIF, by which very small quantities of circulating antibodies are detected by means of their high affinity to fix complement. The first step of this technique is analogous to the first step of IIF, except for the fact that complement in the serum in question is inactivated before hand by heating for 30 minutes at 56°C.<sup>7</sup> If present, serum complement-fixing antibodies bind to the antigen, during incubation with the normal tissue substrate. In the second step, the tissue sections are overlaid with a source of complement, usually a fresh normal human or guinea pig serum. The complement-fixing antibody already

bound to the antigen, activates the complement cascade and generates numerous molecules of C3 at the same time. The third step consists of revealing complement C3 by staining the sections with FITC-conjugates anti-human C3 antibody. Sections are washed in PBS after different incubations. Sections are examined under a fluorescence microscope. As in the indirect technique, positive and negative control sera are applied.<sup>8</sup>

The practical value of this technique is limited to pemphigoid gestationis. HG factor is a complement-fixing anti-BMZ IgG that is present in the sera of patients with PG in minimal amounts, and is not detectable by the standard IIF test. With complement IIF, HG factor can be demonstrated in half of the cases. The assay can be used to confirm the diagnosis where biopsy is unavailable or the results of DIF are equivocal.<sup>3</sup>

### Non-specific fluorescence and autofluorescence

For proper interpretation of specimens of immunofluorescence, specific fluorescence must be distinguished from the non-specific one. Several materials or tissues in the dermis e.g. elastic fibers emit natural autofluorescence, when irradiated by ultraviolet light.<sup>7</sup> Some of the autofluorescence can be blocked with specific absorptive filters. The pale-green fluorescent background of normal epidermis and dermis reflects the non-specific binding of the fluorescent antiserum to the tissue. Mild background fluorescence facilitates identification of different histologic structures, which aid in proper localization of the immunoreactants. Background fluorescence can be minimized by using

**Table 1** Summary of immunofluorescence characteristics of immunobullous diseases [1,2,18]

Diseases	DIF	IIF	IIF on salt-split specimen	Target antigen
Pemphigus group	IgG in ICS in 100% of cases At BMZ & ICS in PNP and PE IgA in ICS in IgA pemphigus	Anti-ICS antibodies in 80% of cases Anti-ICS & BMZ in PNP and PE Ant-ICS of transitional epithelium in PNP	Not applicable	Dsg1 in PF and variants Dsg3 in PV and variants Dsc and Dsp in PNP Dsc1 in IgA pemphigus
Bullous pemphigoid	Linear deposits of IgG±C3 at BMZ	Anti-BMZ antibodies in 70-80%	Anti-BMZ antibodies in the roof exclusively in 80-90%	BP230 BP180
Cicatricial pemphigoid	Linear deposits of IgG±C3 at BMZ	Anti-BMZ antibodies in 20-30%	Epidermal more common, dermal, or mixed pattern	BP180 Laminin 5 (epiligrin)
Pemphigoid gestationis	Linear deposits of C3±IgG at BMZ	Anti-BMZ antibodies in 25%	Epidermal more common	BPAg2180 kDa
Dermatitis herpetiformis	Granular deposits of IgG±C3 at papillary tips or linear granular	No Anti-BMZ antibodies	Dermal staining	?
Linear IgA bullous disease	Linear deposits of IgA±C3 at BMZ	Anti-BMZ antibodies in 80% (childhood) and 30% (adult) type	Epidermal more common, dermal, or mixed pattern	?
Epidermolysis bullosa acquisita	Linear deposits of IgG±C3 at BMZ	Anti-BMZ antibodies in 50%	Dermal floor	Type VII collagen

BMZ=basement membrane zone; BP=bullous pemphigoid; Dsc=desmocollins; Dsg=desmogleins; Dsp=desmoplakins; PE=pemphigus erythematosus; PNP=paraneoplastic pemphigus

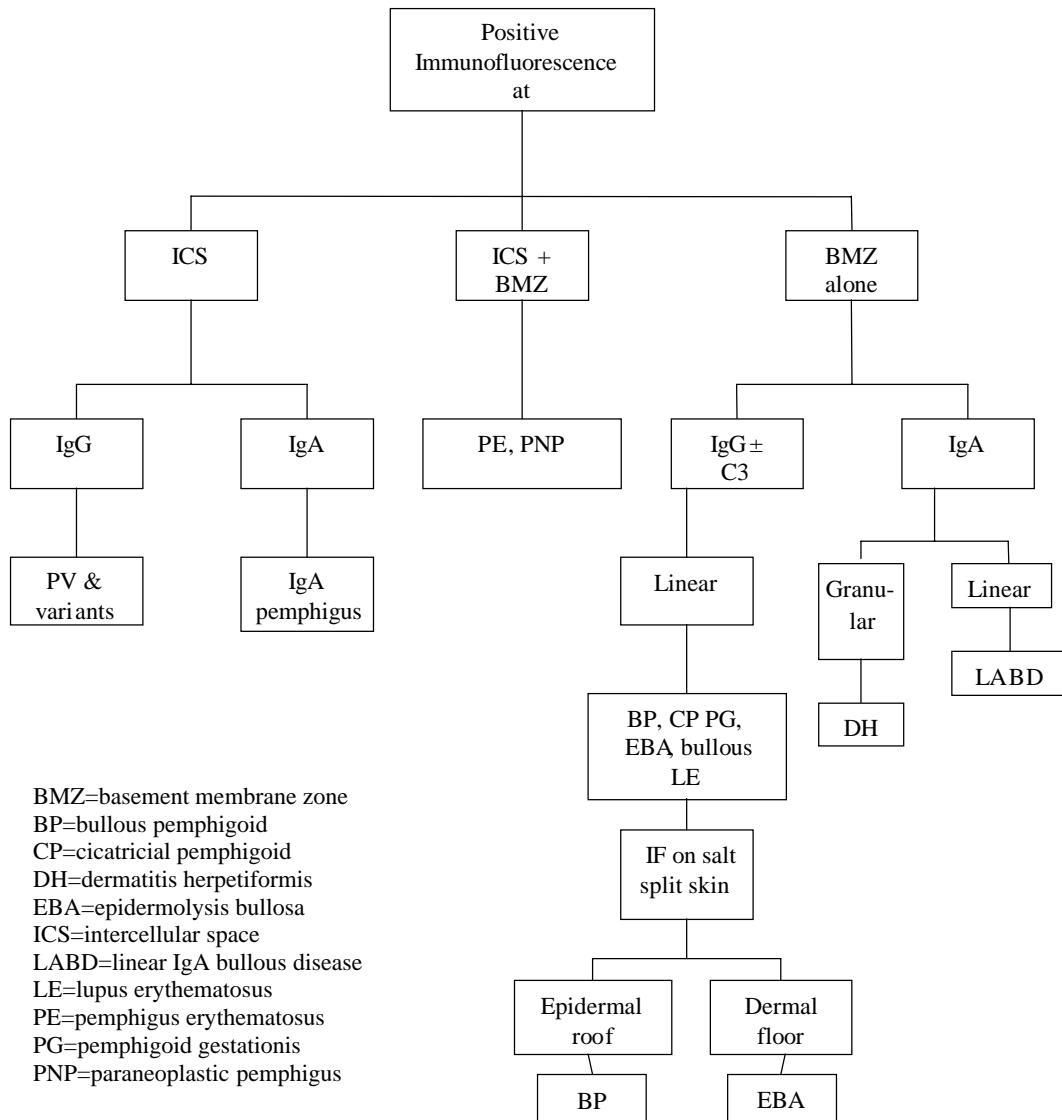
an appropriate dilution of the fluorescein-labeled antiserum. A granular type of non-specific fluorescence is due to the presence of aggregated immunoglobulins in the fluorescent antiserum.<sup>7</sup>

*Interpretation*

**Table 1** shows the immunofluorescence characteristics of different immunobullous diseases.

**I. Direct immunofluorescence**

In interpreting an immunofluorescence specimen, four main features of fluorescence are particularly important; a) main site of deposition; b) the class of immunoglobulin or type of immunoreactant; c) the number of immunoreactants; and d) any deposition in other sites besides the main site. Using these features, a logical and practical approach can lead to an accurate diagnosis in the vast majority of specimen (**Figure 2**).<sup>3</sup>



**Figure 4** Algorithmic approach in case of direct immunofluorescence

**A. Intercellular Space (ICS) Deposition**

Intercellular space (ICS) immunoreactant deposition is seen in pemphigus group.<sup>2</sup> When fluorescence is observed at the inter-cellular space, it is important to note the class of immunoglobulins deposited, their preferential binding to different levels within the epidermis and any associated deposition at other sites.

*i) Deposition of IgG in the ICS only*

Deposition of IgG in the epidermal ICS is the hallmark of pemphigus group of diseases.

*Pemphigus vulgaris, pemphigus foliaceus and their variants* Positive immunofluorescence is seen in 100% patients with active disease, if an appropriate biopsy has been obtained.<sup>3</sup> The IgG belong to IgG1 and IgG4 subclasses. The pattern of fluorescence appears as typical linear deposition on the surfaces of keratinocytes. It resembles a "Chicken

wire or net-work pattern". The epidermal ICS fluorescence seen in both pemphigus vulgaris and pemphigus foliaceus and their variants can be identical; but often fluorescence is limited to or predominant in suprabasal area in PV and the upper epidermal area in PF. However, it is not reliable enough to be used diagnostically.<sup>11</sup> Complement component C3 may be seen in a pattern similar to that of IgG, but with lower frequency and intensity.<sup>1</sup> However, the diagnosis of pemphigus should not be made when only C3 is deposited.

In PV patients, negative DIF finding is a good indicator of remission, as patients with positive results of DIF had major relapses within three months of cessation of therapy.<sup>12</sup>

#### *ii) IgA deposition in the ICS*

If the deposition of immunoreactants in the ICS consists exclusively or predominantly of IgA, the diagnosis of *IgA pemphigus* is made. Intercellular deposition of IgA is observed in the upper epidermis in subcorneal pustular dermatosis (SPD)-type and in the entire epidermis in the intraepidermal neutrophilic (IEN)-type.<sup>13</sup> Patients with pemphigus having both intercellular IgG and IgA antibodies should be differentiated from IgA pemphigus. Aggregated IgA deposits in the stratum corneum in the pustules differ from the pemphigus-like deposits in IgA pemphigus.<sup>13</sup>

#### ***B. Deposition in the ICS and BMZ***

The presence of basement membrane zone deposition, in addition to ICS deposition of IgG, is seen in pemphigus erythematosus and paraneoplastic

pemphigus. In *pemphigus erythematosus*, the fluorescence at BMZ is granular or as a fibrillar band of immune deposits, in addition to a net-work pattern at ICS.<sup>3</sup>

In *PNP*, IgG and C3 are deposited in the ICS and BMZ; however, false-negative DIF is more commonly noticed in *PNP* than in other forms of pemphigus.<sup>11</sup>

#### ***C. Basement Membrane Zone Deposition***

When deposition of immunoreactants in the BMZ is studied, four features have to be observed, which include a) the type of immunoreactants, b) their number, c) morphologic pattern, and d) deposition present at any other site.<sup>3</sup>

#### *i) IgG or C3 deposition at the BMZ*

Deposition of IgG and/or C3, and occasionally other immunoreactants exclusively at the BMZ is seen in BP, CP, PG, EBA, and bullous LE. It is not always easy to differentiate these diseases on the basis of DIF alone. Indirect IF may be needed to confirm the diagnosis. In BP and PG the deposition consists predominantly and occasionally exclusively (especially in PG) of C3.<sup>3</sup> They are present in a continuous, fine and linear pattern.<sup>3</sup>

*Bullous pemphigoid* Linear deposits of IgG and C3 are observed in nearly 100% and approximately 90% of cases, respectively.<sup>7</sup> IgG4 is the predominant isotype. DIF on salt-split specimen shows epidermal mapping in about 50% of cases whereas it is combined in the rest. C3 is of less diagnostic significance. DIF is less sensitive in localized pemphigoid than generalized type.<sup>14</sup> If the perilesional skin

is not available for biopsy then anterior aspect of thigh or flexor aspect of forearm is a suitable alternative site.<sup>15</sup> Biopsy specimens from the legs have a lower yield of positivity.

DIF in lichen planus pemphigoides shows C3 deposits at BMZ.<sup>16,17</sup>

*Pemphigoid gestationis* Homogeneous linear deposits of C3 at the BMZ are seen in almost all active cases.<sup>8</sup> In 30-50% of cases, IgG (IgG1 subclass) may also be present.<sup>18</sup> However, using monoclonal antibodies, IgG1 was demonstrated in all cases. Other immunoreactants infrequently reported include IgA, IgM, C1q, C4 and other complement components. DIF findings may persist for several months after the resolution of cutaneous lesions.

*Cicatricial pemphigoid* Linear deposits of IgG (IgG4 isotype) along with C3 are seen. IgA, IgM, fibrin are rarely seen. DIF on salt-split skin reveals usually epidermal-dermal pattern.<sup>1,8</sup>

*EBA and bullous LE* Both are characterized by tendency for multiple immunoreactant deposition at the BMZ and a different morphologic pattern of deposition.<sup>3</sup> In EBA, intense IgG (IgG1 and IgG4 subclasses) is almost always present, followed by C3 and then IgA and IgM with more variable and relatively weaker intensity.<sup>3</sup> The BMZ deposition tends to be in a thick, broad and homogeneous band.<sup>2</sup> In bullous LE, as in EBA, IgG is invariably present at the BMZ followed by IgA (two thirds) and IgM (one half).<sup>3</sup> In bullous LE, 60% cases show a pattern of deposition similar to that of EBA and in 40% the deposition is in a granular pattern similar to that of non-bullous LE. In the absence of clinical history, it is impossible to distinguish

EBA from bullous LE. The only distinguishing feature between bullous LE and EBA is the presence of other serologic evidence of SLE.<sup>3</sup>

### *Differentiation of BP and EBA*

DIF studies are of limited value in distinguishing between BP and EBA because both are characterized by linear deposition of complement and immunoglobulin along the BMZ.<sup>19</sup> Electron microscopy, immunoelectron microscopy and Western blotting differentiate the two diseases, but these are time-consuming, expensive and are available at few centers.<sup>20</sup> The use of DIF and IIF tests on either salt-split patient skin or salt-split substrate, respectively is helpful in resolving this dilemma.<sup>15</sup> IIF on salt-split substrate reveals epidermal binding in BP whereas dermal binding occurs in EBA. Dermal deposition is infrequently seen in anti-laminin 5 CP and protein 105 BP. Nonetheless, approximately 25% of BP patients and 50% of EBA patients do not possess detectable circulating antibodies, therefore IIF on salt-split skin is of no help for a great number of patients. In these cases DIF on salt-split skin can distinguish between BP (deposition in the epidermal roof) and EBA (deposition in the dermal floor) with certainty.<sup>21</sup>

Fluorescent overlay antigen mapping is another technique used to differentiate between BP and EBA. Using different fluorescent markers, mapping the known location of red-labelled type VII collagen to the unknown location of green-labelled IgG deposits is done. In BP, a nonoverlapping pattern composed of interfacing and partially merging red and green bands is seen which differs from overlapping pattern of EBA.<sup>22</sup>

ii) *IgA deposition at the BMZ only*

Given the clinical and histopathologic overlap that exists between DH, linear IgA disease and other subepidermal bullous diseases, the IF findings are of paramount importance in distinguishing between these disorders.<sup>19</sup>

*Dermatitis herpetiformis* The most specific immunopathologic finding and diagnostic criterion of DH is the granular deposition of IgA in the papillary dermis of uninvolved skin.<sup>3</sup> Granular deposits are usually located at the tips of dermal papillae within the microfibril bundles but they may also extend as a band along the BMZ especially if the epidermis is flat.<sup>23,24</sup> IgA belongs to IgA1 subclass, IgA2 was found in one study. J-chains and secretory components are also present, suggesting that IgA is of mucosal origin. C3 is commonly found particularly in patients who are not on gluten-free diet.<sup>24</sup>

*Linear IgA disease* Both childhood form and adult LAD will show a linear band of IgA deposition at the BMZ.<sup>23</sup> IgA belongs to IgA1 isotype and lacks J-chains and secretory component.<sup>23</sup> Rarely, other immunoreactants such as C3, IgM and IgG are found with IgA by direct IF.<sup>23</sup> DIF on salt-split skin gives heterogeneous pattern, dermal, epidermal and combined, all are reported.<sup>23</sup>

## II. Indirect Immunofluorescence (IIF)

While interpreting IIF, it is important to note a) the class of circulating antibody; and b) the site of its binding. The vast majority of circulating antibodies belong to the IgG class in BP, CP, PG, EBA and bullous LE. IgA is characteristic of LAD and IgA pemphigus. No circulating antibodies are demonstrable in DH.<sup>3</sup>

## A. Anti-ICS antibodies

### i) *IgG class*

*Pemphigus* Circulating IgG anti-ICS antibodies in a chicken wire pattern are characteristic of PV (80-90%), PF (60-80%), PE, some cases of drug-induced pemphigus and PNP.<sup>3,11</sup> Monkey esophagus is the sensitive and specific substrate for PV and guinea pig tissue (esophagus or lip) is the preferred substrate for PF. The titer of anti-ICS antibodies correlates with the activity of pemphigus and thus can be used to follow progress and response to therapy.<sup>3</sup>

*Paraneoplastic pemphigus* In addition to ICS, some IgG deposits are also seen at BMZ. Antibodies in PNP differ from those of other forms of pemphigus in that they bind the ICS of simple and transitional epithelia (rodent bladder) in addition to stratified squamous epithelia.<sup>3</sup> Immunoprecipitation studies are more sensitive than IIF but are more time consuming and expensive.<sup>11</sup>

### ii) *IgA Class*

*IgA pemphigus* IgA anti-ICS antibodies are characteristic of IgA pemphigus.<sup>3</sup> These are detected in about 50% of cases. Deposition occurs in the upper epidermis in SPD-type and entire epidermis in IEN-type.

## B. Anti-BMZ antibodies

### i) *IgG class*

These antibodies are present in the sera of patients with BP, CP, PG, EBA and bullous LE. A positive result of IIF does not differentiate among the various IgG-mediated subepidermal bullous diseases, although binding tends to be broader and more homogeneous in EBA than in pemphigoid variants.<sup>3</sup>

*Bullous pemphigoid* The frequency of a positive result of IIF on intact substrates is approximately 70-80% for BP. They are not predictive of disease severity. IIF on salt-split skin, reveals circulating autoantibodies in 90% of patients, and these usually bind to epidermal roof.<sup>3</sup> Using monoclonal antibodies, it has been shown that serum autoantibodies are mainly anti-BP230.<sup>25</sup> Serum level of anti-BP180 correlates with the disease activity and can be used as a guide for therapy.<sup>26</sup>

*Pemphigoid gestationis* IgG (IgG1 class) serum anti-BMZ antibodies are detected in only 20% of patients but can be demonstrated in 100% of cases if monoclonal antibodies are used. HG, an avidly complement-fixing IgG antibody, is found in 50% of cases.<sup>1,18</sup>

*Cicatricial pemphigoid* Circulating autoantibodies are found in 20% of cases and these give heterogeneous pattern on salt-split specimen.<sup>1,18</sup>

*Lichen planus pemphigoides* IgG deposits are seen at BMZ.<sup>14,15</sup>

*Epidermolysis bullosa acquisita* About 50% of patients with EBA have serum autoantibodies.<sup>3</sup> IIF on salt-split skin shows the dermal pattern of deposition. This is helpful in differentiating between EBA and BP.<sup>27</sup>

#### ii) IgA class

*Linear IgA disease* Circulating autoantibodies are found in 80% of children and 30% of adults with LAD. These belong to IgA1 subclass.<sup>28</sup> Normal human skin and monkey esophagus both can be used as substrate. IIF on salt-split substrate demonstrates epidermal, dermal

and combined patterns, with epidermal being the most common.<sup>1,23</sup>

#### Advantages of Immunofluorescence

Immunofluorescence is a relatively simple and reproducible technique. One advantage of the technique is the short procedure time. The complete procedure including the preparation of sections, their staining and observation can be performed in one to three hours.<sup>4</sup>

Another characteristic is its sensitivity. The sensitivity of the direct method seems to correspond to that of the classical complement fixation test.<sup>4</sup> Sensitivity of the indirect or complement method is estimated to be between five and ten times higher than that of the direct one. IIF, besides the diagnostic importance, has a substantial prognostic value, particularly for pemphigus cases.<sup>12</sup>

#### Disadvantages of immunofluorescence

Immunofluorescence technique is based on a delicate immune reaction. Careful examination and selection of materials, and skillful observation and judgement must be made under adequate optical systems for proper evaluation. Specific fluorescence must be distinguished from nonspecific fluorescence.

#### Future Prospects

Newer techniques like immunoprecipitation technique, Western blot analysis,<sup>29</sup> ELISA<sup>30,31</sup> are increasingly being used in the domain of immunobullous diseases. However, these investigations are complex, expensive and more time consuming. Immunofluorescence still retains its role in this field. Use of newer substrates e.g.

tissue explant culture,<sup>32</sup> specimens from patients with inherited epidermolysis bullosa etc. and monoclonal antibodies may enhance the sensitivity and specificity of this cheap and effective diagnostic tool.

## References

1. Wojnarowska F, Eady RA, Burge SM. Bullous eruptions. In: Champion RH, Burton JL, Burns DA, Breathnach SM, eds. *Textbook of Dermatology*. 6<sup>th</sup> edn. Oxford: Blackwell Science; 1998. p. 1817-98.
2. Kamarashev J. Immunohistochemical techniques for light microscopy. In: Kanihakis J, Vassileva S, Woodly D, eds. *Diagnostic immunohistochemistry of the skin*. 1<sup>st</sup> edn. London: Chapman and Hall Medical; 1998. p. 5-18.
3. Mustasim DF, Pelc NJ, Supapannachart N. Established methods in the investigation of bullous diseases. *Dermatol Clin* 1993; **11**: 399-418.
4. Ueki H, Yaoita H, eds. *A Color Atlas of Dermato-immunohistocytology*. 1<sup>st</sup> edn. Tokyo: Wolfe Medical Publications; 1989.
5. Holubar K. Autoimmune skin diseases since 1963. *Dermatology* 1994; **189** (Suppl 1): 3-5.
6. Kirtsching G, Wojnarowska F. Autoimmune blistering diseases: An update of diagnostic methods and investigations. *Clin Exp Dermatol* 1994; **19**: 97-112.
7. Valenzuela R, Bergfeld WF, Deodhar SD, eds. *Interpretation of immunofluorescent patterns in skin diseases*. 1<sup>st</sup> edn. Chicago: American Society of Clinical Pathologists Press; 1984.
8. Vassileva S. Immunofluorescence in dermatology. *Int J Dermatol* 1993; **32**: 153-61.
9. Feliciani C, DiMuzio M, Mohammad-Pour S *et al.* 'Suction-split' as a routine method to differentiate epidermolysis bullosa acquisita from bullous pemphigoid. *J Eur Acad Dermatol Venereol* 1998; **10**: 243-7.
10. Bhogal BS, Black MM. Diagnosis, diagnostic and research techniques. In: Wojnarowska F, Briggaman RA, eds. *Management of blistering diseases*. 1<sup>st</sup> edn. London: Chapman and Hall Medical; 1990. p. 15-34.
11. Nousari HC, Anhalt GH. Pemphigus vulgaris, paraneoplastic pemphigus and pemphigus foliaceus. In: Kanihakis J, Vassileva S, Woodly D, eds. *Diagnostic immunohistochemistry of the skin*, 1<sup>st</sup> edn. London: Chapman and Hall Medical; 1998. p. 79-83.
12. Ratnam KV, Rang BK. Pemphigus in remission: value of negative direct immunofluorescence in management. *J Am Acad Dermatol* 1994; **30**: 547-50.
13. Iwatsuki K. IgA pemphigus. In: Kanihakis J, Vassileva S, Woodly D, eds. *Diagnostic immunohistochemistry of skin*. 1<sup>st</sup> edn. London: Chapman and Hall Medical; 1998. p. 95-104.
14. Weigand DA, Clements MK. Direct immunofluorescence in bullous pemphigoid: effect of extent and location of lesions. *J Am Acad Dermatol* 1989; **20**: 437-40.
15. Anstey A, Venning V, Wojnarowska F *et al.* Determination of the optimum site for diagnostic biopsy for direct immunofluorescence in bullous pemphigoid. *Clin Exp Dermatol* 1990; **15**: 438-41.
16. Hsu S, Ghohestani RF, Uitto J. Lichen planus pemphigoides with IgG autoantibodies to 180 kd bullous pemphigoid antigen (type XVII) collagen. *J Am Acad Dermatol* 2000; **42**: 136-41.
17. Skaria M, Salomon D, Jaunin F *et al.* IgG autoantibodies from a lichen planus pemphigoides patient recognize the NC16A domain of the bullous pemphigoid antigen 180. *Dermatology* 1999; **199**: 253-5.
18. Katz SI. Herpes gestationis (pemphigoid gestationis). Freedberg IM, Eisen AZ, Wolff K *et al.*, eds. *Dermatology in general medicine*. 5<sup>th</sup> edn. New York: McGraw-Hill; 1998. p. 686-9.
19. Gammon WR, Fine JD, Forbes M, Briggaman RA. Immunofluorescence on salt-split skin for the detection and differentiation of basement membrane zone autoantibodies. *J Am Acad Dermatol* 1992; **27**: 79-87.
20. Smoller BR, Woodley DT. Differences in direct immunofluorescence staining patterns in epidermolysis bullosa acquisita and bullous pemphigoid. *J Am Acad Dermatol* 1992; **27**: 674-8.
21. Hultsch ND, Bisalbutra P, Gammon WR, Yancey KB. Direct immunofluorescence microscopy on 1 mol/L sodium chloride-

- treated patient skin. *J Am Acad Dermatol* 1991; **24**: 946-51.
22. de Jong MC, Bruins S, Heeres K *et al*. Bullous pemphigoid and epidermolysis bullosa acquisita: differentiation by fluorescent overlay antigen mapping. *Arch Dermatol* 1996; **132**: 151-7.
  23. Banfield CC, Allen J, Wojnarowska FT. Dermatitis herpetiformis and linear IgA disease. In: Kanitakis J, Vessileva S, Woodley D, eds. *Diagnostic immunohistochemistry of the skin. 1<sup>st</sup> edn*. London: Chapman and Hall Medical; 1998. p. 105-13.
  24. Zone JJ, Meyer LT, Petersen MJ. Deposition of granular IgA relative to clinical lesions of dermatitis herpetiformis. *Arch Dermatol* 1996; **132**: 912-8.
  25. Pas HH, de Jong MC, Jonckman MF *et al*. Bullous pemphigoid antibody titre and antigen specificity. *Exp Dermatol* 1995; **4**: 372-6.
  26. Schmidt E, Obe K, Brocker EB, Zillikens D. Serum levels of autoantibodies to BP180 correlate with disease activity in patients with bullous pemphigoid. *Arch Dermatol* 2000; **136**: 174-8.
  27. Mustasim DE. The accuracy of indirect immunofluorescence on sodium chloride-split skin in differentiating subepidermal bullous diseases. *Arch Dermatol* 1997; **133**: 1158-60.
  28. Egan CA, Martineau MR, Taylor TB *et al*. IgA antibodies recognizing LABD97 are predominantly IgA1 subclass. *Acta Derm Venereol* 1999; **79**: 343-6.
  29. Guidice GJ, Diaz LA. New laboratory methods in the investigation of bullous disease. *Dermatol Clin* 1993; **11**: 419-27.
  30. Lenz P, Amagai M, Platzer BV *et al*. Desmoglein 3 ELISA: a pemphigus vulgaris-specific diagnostic tool. *Arch Dermatol* 1999; **135**: 143-8.
  31. Nishikawa T. Desmoglein ELISAs: a novel diagnostic tool for pemphigus. *Arch Dermatol* 1999; **135**: 195-7.
  32. Mustasim DF, Vaughan A, Supapannachart N, Farooqui J. Skin explant culture: a reliable method for detecting pemphigoid antibodies in pemphigoid sera by standard immunofluorescence and immunoblotting. *J Invest Dermatol* 1993; **101**: 624-7.

