

Quiz

An erythematous nodule on arm

Faria Asad, Sabrina Suhail Pal

Department of Dermatology, King Edward Medical College/Mayo Hospital, Lahore

Report of a case

A 52-years-old female presented with a slowly enlarging, asymptomatic, solitary erythematous nodule on the lateral aspect of her left arm for the last three months. Her medical record was significant. Ten years earlier, she had adenocarcinoma of right breast which was surgically removed successfully and there was no evidence of metastasis at that time.

Physical examination revealed a well-defined, firm, 1.5x2 cm, erythematous, non-tender nodule on the outer aspect of the left arm. No axillary lymphadenopathy was found. The patient denied any constitutional symptoms. Her systemic examination and laboratory investigations were unremarkable. A biopsy was performed (**Figure 1 & 2**).

What is your diagnosis?

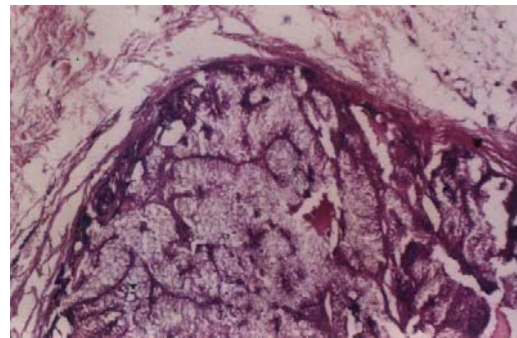


Figure 1 (haematoxylin-eosin, original magnification x 40)

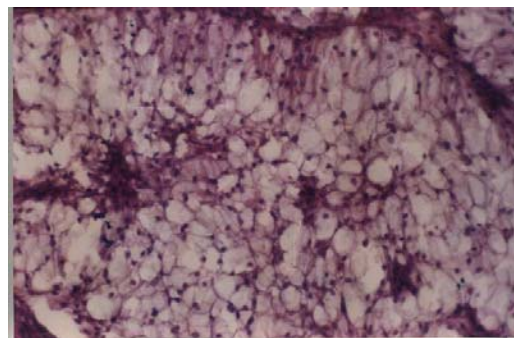


Figure 2 (haematoxylin-eosin, original magnification x 400)

Address for Correspondence

Dr. Faria Asad,
Department of Dermatology,
Mayo Hospital, Lahore.

Diagnosis

Clear cell hidradenoma

Microscopic findings and clinical course

Section of the biopsy specimen showed a large well circumscribed tumor extending from the reticular dermis to the subcutaneous fat. It was composed of multiple lobulated masses. Within the lobules few cystic spaces were present containing homogeneous eosinophilic material. In the solid portion of the tumor there were two types of cells. The majority were polygonal having a round nucleus and very clear cytoplasm. The other cells were fusiform having basophilic cytoplasm arranged at the periphery. No nuclear atypia was seen. The histological features were typical of clear cell hidradenoma.

The patient was referred for surgical excision of the nodule.

Discussion

Clear cell hidradenoma is a benign tumor of eccrine glands. It usually occurs as an asymptomatic slowly growing nodule.¹ Generally solitary, but rarely several lesions may be present. It is covered by intact skin but may ulcerate and discharge serous fluid.² Diagnosis is by histopathology. Various names have been given to this tumour e.g. clear cell

papillary carcinoma, clear cell myoepithelioma, eccrine acrospiroma etc. Many of these names highlight the presence of clear cells which constitute a large proportion of the tumor. Clear cells contain glycogen and eccrine type enzymes in high concentration. Malignant transformation can occur but it is very rare.³ Mohs' micrographic surgery is the treatment of choice.⁴

Primary breast cancer frequently involves the skin and may present as nodules. Although, the tumour in our patient was benign, it is imperative to consider cutaneous metastasis in any patient with a new skin lesion who has a history of carcinoma.

References

1. Feldman AH, Niemi WJ, Blume PA *et al.* Clear cell hidradenoma of the second digit: a review of the literature with case presentation. *J Foot Ankle Sur* 1997; **36**: 21-3.
2. Schweitzer WJ, Goldin HM, Bronson DM *et al.* Ulcerated tumor on the scalp. Clear cell Hidradenoma. *Arch Dermatol* 1989; **125**: 985-6.
3. Touma D, Laporte M, Goossens A *et al.* Malignant clear cell hidradenoma. *Dermatol* 1993; **186**: 284-6.
4. Will R, Coldiron B. Recurrent clear cell hidradenoma of foot. *Dermatol Sur* 2000; **26**: 985-6.

