

## Case Report

# Acute febrile neutrophilic dermatosis (Sweet's syndrome) in childhood: two case reports and review

Mohammad Taghi Noorbala\*, Ali Fatahi Bafghi\*\*

\*Dermatology Department, Shahid Sadoughi Medical Science University of Yazd, Iran.

\*\*Parasitology Department, Shahid Sadoughi Medical Science University of Yazd, Iran.

**Abstract** Sweet's syndrome is rare in children. Usually, heralded by tender polymorphous skin lesions, typically accompanied by fever and peripheral neutrophilia, can easily be mistaken for infection and lead to many antibiotic administration. Such therapy does not improve disease, which is thought to represent an immunologic reaction to agents as diverse as infection, neoplasia, or drugs.

We report two boys, six and nine-year-old who suffered from acute febrile neutrophilic dermatosis. Both were febrile, had leukocytosis, and exhibited characteristic clinical and histopathologic lesions. They had an antecedent trauma, and responded to systemic corticosteroids. Our evaluation and long term follow-up of these children failed to reveal evidence of underlying malignancy or a chronic systemic illness typically encountered in Sweet's syndrome.

### **Key words**

Sweet's syndrome, septicemia, children, corticosteroid.

### **Introduction**

Sweet's syndrome is a relatively rare and worldwide disease with no racial predilection. Although it may be seen at any age, but usually occurs in women at 4th or 5th decades of life.<sup>1,2</sup> The disease usually starts with high grade and persistent fever accompanied by severe ill condition (a septic shock picture). Later, skin lesions in the form of nodules or erythematous plaques (irregular and very sensitive), will appear on the forearm and neck. The lesions progress either into a wound or are filled with vesicles and pustules after 2-4 weeks.

Sometimes wound heals centrally without leaving scar, but may progress to the surrounding area.<sup>1,2</sup>

The others symptoms such as arthralgia, arthritis, conjunctivitis, and various mucus membrane lesions also have been reported in association with skin symptoms. In addition, many chronic inflammatory diseases, a variety of cancers mostly cancers of lymphoreticular system have been observed in accompany with disease.<sup>1-6</sup>

Increased neutrophils in peripheral blood with high erythrocyte sedimentation rate (ESR) is one of the important laboratory findings. Microscopic characteristic of the syndrome is comprising local and severe infiltration of neutrophils and, to lesser extent, eosinophils or lymphocytes in dermis.<sup>1,2</sup>

---

### **Address for correspondence**

Dr. M.T. Noorbala  
Department of Dermatology,  
Shahid Sadoughi Medical Science University,  
Yazd - Iran  
E mail: mtnoorbala@gmail.com

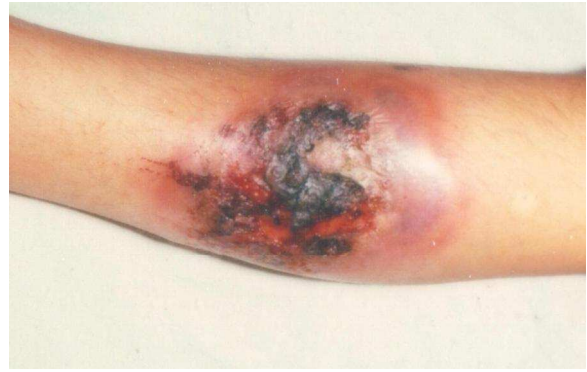Although it occurs typically in adults, rarely, infants and children are affected. To our knowledge, a few cases in adults have been reported from Iran.<sup>7</sup> We report two children with Sweet's syndrome in Yazd, Iran.

### Case 1

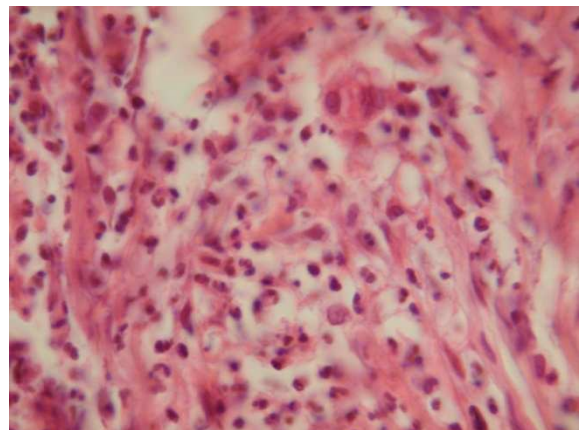
*History* A 6-year-old boy in a very ill state with high fever was admitted to the pediatric ward on March, 2001 (Shahid Sadoughi Hospital). His dilemma started ten days before his admission after injury to his leg which gradually progressed and did not respond to any conventional treatment. He was diagnosed as septicemia and treatment started with extensive antibiotics by pediatrician. However, after five days no improvement was observed and a consultation with dermatologist was requested.

*Physical examination* At the time of dermatological consultation, the patient was very ill with high grade fever and had skin lesions in a range of tender erythematous papules, pustules and plaques from few millimeters to few centimeters, located mainly on his legs and forearms. Some plaques were ulcerated and filled with pus, necrotic tissue and partly covered with crust (**Figure 1**). Severe pain due to arthralgia caused flexion of the knees, but sign of arthritis were not observed. Several small size scars of 0.5 to 1 cm diameter, on patient's lower extremities were found, secondary to previous trauma. Other pathological findings, especially lymphadenopathy were not observed on systemic examination.

*Laboratory data* White blood cell count (WBC) = 31000/mm<sup>3</sup> with polys=80% and lymphocytes=20%, hemoglobin (Hb)=12.7, erythrocyte sedimentation rate (ESR) for first



**Figure 1** An ulcerated plaque with necrotic tissue and crusts on forearm.



**Figure 2** Rich neutrophilic infiltrate in the dermis.

and second hour, respectively = 66 and 110mm. The morphology of red and white blood cells as well as immunoglobulins G, A, M were reported as normal.

*Histopathology* Hematoxylin and eosin-stained sample from leg plaque showed slight spongiosis and superficial erosions scattered in some areas of epidermis, but essential changes seen in the upper and middle part of the dermis were in the form of severe neutrophilic infiltration with scattered lymphocytes (**Figure 2**). Infiltration of neutrophils extended to hair follicles and some extent epidermis. In a number of areas, neutrophil nuclear dust and proliferation of the vascular endothelial cells was observed.

Diagnosis of Sweet's syndrome was established and treatment with prednisolone (1mg/kg/day) started and all other medications discontinued. After two days, the fever abated and about five days later the majority of patient's symptoms also disappeared. The skin lesions were in remission with reepithelialization. The laboratory results on seventh days later were: WBC=21800/mm<sup>3</sup> with poly=48% and lymph=54%, Hb=12 and ESR=38, 75mm. Ten days following treatment, patient was discharged in good condition with skin lesions healing. His treatment with prednisolone was maintained at half dosage and gradually reduced and finally stopped after two months.

Lesions recurred twice. First, in January 2002, which were treated with 10 mg/day of prednisolone and the other one in August, 2003 with more severe manifestations requiring hospitalization and treatment with high dose of prednisolone (50mg/day). Few weeks after control of disease, dose of prednisolone was tapered to eventually 30 mg/day but no lower. Thereafter, occasionally new skin lesions occurred and then the patient was symptom free.

Five years after beginning of the disease, on April, 2006, patient underwent surgery on his left eye to remove his cataract. He lost his infected eye following surgery. It was decided to cancel the surgery in his right eye. Patient's growth and development especially his height declined and some new lesions occasionally also appeared. In September, 2006 since patient had another flare-up of the disease with new skin lesions, 50 mg azathioprine was added to 30 mg prednisolone and patient was relatively better with this new regimen. Six months later, azathioprine was replaced with 100mg cyclosporine for better control, although new lesions were still developing and the disease was

under relative control. Search did not reveal any underlying disease or malignancy.

## **Case 2**

*History and physical examination* The patient was a 9-year-old boy with a variety of papular erythematous and bullous lesions accompanied with petechiae and purpura on lower extremities predominantly on legs. The disease started with mild fever and slight pain in the left knee after mild trauma to his leg one week before. Slowly the skin lesions appeared and after finding hematuria 1+ in his urine analysis he was referred to nephrologist and admitted. In the end, he consulted a dermatologist and complementary tests and skin biopsy from lesion were requested.

*Laboratory data* WBC=17000/mm<sup>3</sup> with polys=78% and lymphos=21%, Hb=13.1 g/dl, ESR=45, 70 mm. Repeat urinalysis showed hematuria 1+.

*Histopathology* Skin biopsy revealed severe infiltration of dermis with neutrophils and slight nuclear dust; severe edema of dermis and spongiosis of epidermis.

Clinical symptoms and the laboratory findings led to a diagnosis of Sweet's syndrome and subsequently treatment with prednisolone (1mg/kg/day) was started. Seven to ten days following treatment, patient's entire symptoms disappeared leaving just atrophic scars on skin. Prednisolone was gradually decreased and after two months reached its minimum dose until three months later discontinued. Since then no recurrence of the disease has been observed.

## **Discussion**

The cause of Sweet's syndrome is still unknown.

It has been accompanied with or occurred after infectious diseases especially of upper respiratory system.<sup>8</sup> The syndrome has also been reported in association with salmonella<sup>9</sup> and yersinia,<sup>10</sup> as well. Dunn *et al.* in 1992 observed seventeen cases of this syndrome in concurrence with different infection diseases.<sup>11</sup> The syndrome has frequently been reported with chronic granulomatous disease,<sup>12</sup> systemic lupus erythematosus,<sup>13</sup> leukemia,<sup>14,15</sup> multiple myeloma,<sup>16</sup> lyposarcoma,<sup>17</sup> and other cancers.<sup>18,19</sup>

However, in our patients the search to discover any underlying disease led to no pathological findings. In many cases, Sweet's syndrome precedes any apparent illness and only in subsequent months or even years after diagnosis of Sweet's syndrome, the original disease manifests itself. Therefore, it is crucial to consider other simultaneous diseases when one diagnoses Sweet's syndrome. In case of no apparent underlying/associated disease, further investigations at adequate intervals should be executed. It has also been noted that in cases with no background illness, the syndrome recurs frequently.

Syndrome may result from a hypersensitivity reaction to an eliciting factor such as bacteria, virus, or tumor antigen.<sup>1,2</sup> The appearance, histopathology and course of the skin lesions suggest this concept. In addition, the prompt response of both symptoms and lesions to corticosteroids supports this hypothesis. Leukotactic mechanisms, dermal dendrocytes, circulating autoantibodies, immune complexes, HLA serotypes, and cytokines have all been postulated to contribute to the pathogenesis of disease.<sup>2</sup>

Since the disease generally commences with an acute, severe, and toxic picture, septicemia is considered as the initial diagnosis and hence it is

firstly treated with widespread antibiotics with virtually no clinical response. As differential diagnosis, therefore, other acute and toxic diseases such as erythema multiforme, vasculitis, TEN, and then some chronic granulomatous diseases especially pyoderma gangrenosum should be considered. The disease can occur at any age but has frequently been reported in children.<sup>11,21,22</sup>

The proposed diagnostic criteria for Sweet's syndrome as mentioned in the reference text of dermatology, the patients must have both of the two major criteria and at least two of the four minor criteria for the diagnosis.<sup>1</sup>

**Major criteria:** 1. Acute onset of typical skin lesions, 2. Typical histopathological findings

**Minor criteria:** 1. Fever over 38°C or general malaise, 2. Association with malignancy, inflammatory disorder, pregnancy, antecedent respiratory or gastrointestinal infection, 3. Excellent response to systemic corticosteroids or potassium iodide (KI), 4. Abnormal laboratory values at presentation (three of four required: ESR >20 mm; leukocytes >8000/mm<sup>3</sup>; neutrophils >70%, and positive C-reactive protein.

The duration of disease varies from one to eight months. The best medication is systemic corticosteroids which treat the symptoms promptly. The fever and the general illness improve after a few days while the lesions disappear within one or two weeks. Potassium iodine, clofazimine, colchicine, indomethacin, and retinoids have also proved to be useful.<sup>23,24</sup> Generally, prednisolone (0.5-1 mg/kg) is sufficient to control the disease. In recovery phase, it is feasible to decrease the dose of the drug until one or two months later when it can be discontinued.

Although the illness described by Sweet's and others is usually benign,<sup>25</sup> in a significant group of patients, including children, the syndrome either accompanies or precedes the development of myelogenous leukemia.<sup>3,12, 22</sup> Clearly, such an association requires increased awareness of the Sweet's syndrome among pediatricians

To date, nearly 40 cases have been described in the pediatric literature, the patients ranging in age from 10 and 15 days in two brothers<sup>2</sup> to 12 years.<sup>5,6, 8, 26</sup>

Lesions may develop at sites of previous skin trauma (pathergy), only four such cases have been previously reported.<sup>27</sup> Our cases also support this association.

The majority of pediatric patients with Sweet's syndrome treated with oral steroids respond very rapidly with clearance of the lesions, and only 3 children have been reported as requiring maintenance steroids.<sup>27</sup> Spontaneous clearance of the lesions of Sweet's syndrome has also been reported in 2 cases.<sup>27</sup> Our patients responded to oral steroids with rapid resolution of fever and skin lesions, which healed with scar formation. In the first patient, we could not discontinue steroids and he needed maintenance therapy.

## References

1. Barham KL, Jorizzo JL, Grattan B, Cox NH. Vasculitis and neutrophilic vascular reactions. In: Burns T, Breathnach S, Cox N, Griffiths C, editors. *Rook's Textbook of Dermatology*, 7<sup>th</sup> edn. Oxford: Blackwell Science, 2004. P. 49.1-49.46.
2. Cohen PR, Hönigsmann H, Kurzrock R. Acute febrile neutrophilic dermatosis (Sweet's syndrome). In: Wolff K, Goldsmith LA, Katz SI *et al.*, editors. *Fitzpatrick's Dermatology in General Medicine*, 7<sup>th</sup> edn. New York: McGraw-Hill; 2008. P. 289-95.
3. Caughman W, Stern R, Haynes H. Neutrophilic dermatosis of

- myeloproliferative disorder. *J Am Acad Dermatol* 1983; **9**:751-8. PMID: 6358279
4. Cohen Pr, Kutzrock R. Sweet's syndrome and malignancy. *Am J Med* 1987; **82**: 1220-6. PMID: 3300306
5. Delaporte E, Gavoau DJ, Piette FA, Bergoënd HA. Acute febrile neutrophilic dermatosis. *Arch Dermatol* 1989; **125**: 1101-4. PMID: 2757408
6. Garty BZ, Levy I, Nitzan M, Barak Y. Sweet's syndrome associated with G-CSF treatment in a child with glycogen storage disease type Ib. *Pediatrics* 1996; **97**: 401-3. PMID: 8604280
7. Zamanian A, Ameri A. Acute febrile neutrophilic dermatosis (Sweet's syndrome): a study of 15 cases in Iran. *Int J Dermatol* 2007; **46**: 571-4. PMID: 17550553
8. Sweet's RD. Acute febrile neutrophilic dermatosis. *Br J Dermatol* 1978; **100**: 93-9. PMID: 427014
9. Karmochkine M, Villette B, Christoforov B, Escande JP. Association of Sweet's syndrome and salmonellosis. *Rev Med Interne* 1991; **12**: 238-9. PMID: 1896720
10. Neau D, Monlun E, Delmas M *et al.* Sweet's syndrome and *Yersinia enterocolitica* infection. 2 cases." *Rev Med Interne* 1995; **16**: 919-22. PMID: 8570955
11. Dunn TR, Saperstein HW, Biederman A, Kaplan RP. Sweet's syndrome in a neonate with aseptic meningitis. *Pediatr Dermatol* 1993; **10**: 298-9. PMID: 1488383
12. Sedel D, Huguet P, Lebbe C *et al.* Sweet's syndrome as the presenting manifestation of chronic granulomatous disease in an infant. *Pediatr Dermatol* 1994; **11**: 237-40. PMID: 7971558
13. Katayama I. Subacute lupus erythematosus and Sweet's syndrome. *Int J Dermatol* 1992; **31**: 165. PMID: 1568805
14. Kannan R, Dutta TK, Goel A *et al.* Sweet's syndrome in chronic myeloid leukemia. *Postgrad Med J* 1995; **71**: 383. PMID: 7644412
15. Salmon-Ehr V, Estève E, Serpier H *et al.* Acute febrile pustular and bullous neutrophilic dermatosis (Sweet's syndrome) disclosing acute myeloblastic leukemia. *Rev Med Interne* 1995; **16**: 347-50. PMID: 7597321
16. Yokoyama K, Kojima M, Komatsumoto S *et al.* Acute megakaryoblastic leukemia associated with Sweet's syndrome, including review of the literature. *Rinsho Ketsueki* 1993; **34**: 341-7. PMID: 8479086

17. Geelkerken RH, Lagaay MB, van Deijk WA, Spaander PJ. Sweet's syndrome associated with liposarcoma: a case report. *Neth J Med* 1994; **45**: 107-9. PMID: 7969662
18. Cohen PR, Holder WR, Tucker SB *et al.* Sweet's syndrome in patients with solid tumors. *Cancer* 1993; **72**: 2723-31. PMID: 8402496
19. Cuny R. A case from practice (249). Sweet's syndrome in triple carcinoma. *Schweiz Rundsch Med Prax* 1992; **81**: 1030-2. PMID: 1329174
20. Bourke JF, Keohane S, Long CC *et al.* Sweet's syndrome and malignancy in the U.K. *Br J Dermatol* 1997; **137**: 609-13. PMID: 9390341
21. Hazen PG, Kark EC, Davis BR *et al.* Acute febrile neutrophilic dermatosis in children: report of two cases in male infants. *Arch Dermatol* 1983; **119**: 998-1002. PMID: 6651317
22. Maleville J, Taïeb A. Acute febrile neutrophilic dermatosis in childhood (Sweet's syndrome). *Pediatr Dermatol* 1993; **10**: 298-9. PMID: 8415316
23. Tomas JF, Escudero A, Fernandez-Ranada JM. All-trans retinoic acid treatment and Sweet's syndrome. *Leukemia* 1994; **8**: 1596. PMID: 8090038
24. Jeanfils S, Joly P, Young P *et al.* Indomethacin treatment of eighteen patients with Sweet's syndrome. *J Am Acad Dermatol* 1997; **36**: 436-9. PMID: 9091476
25. Sweet's RD. An acute febrile neutrophilic dermatosis. *Br J Dermatol* 1964; **76**: 349-56. PMID: 14201182
26. Ly S, Beylot-Barry M, Beyssac R *et al.* Sweet's syndrome associated with Crohn disease. *Rev Med Interne* 1995; **16**: 931-3. PMID: 8570958
27. Kourtis AP. Sweet's Syndrome in infants. *Clin Pediatr (Phila)* 2002; **41**: 175-7. PMID: 11999681

For timely delivery of JPAD, members of Pakistan Association of Dermatologists are requested to update their mailing address with editorial office.