

## Case Report

# Post herpes zoster ophthalmicus acneiform eruption: a case report

Mansoor Haider, Issam Hamadah

Dermatology Unit, King Faisal Specialist Hospital and Research Centre, Riyadh, Saudi Arabia

**Abstract** Appearance of comedones or acneiform eruption following herpes zoster infection as an isotopic response is a rare occurrence. We report a case of acneiform eruption in healed herpes zoster ophthalmicus in a middle aged man.

**Key words**

Herpes zoster, acne, comedones

### Introduction

Herpes zoster results from reactivation of varicella-zoster virus (VZV) which remains latent in dorsal root ganglia following primary infection. It may be followed by neurological, dermatological and ophthalmologic complications especially in elderly and immunocompromised persons.

Zoster-associated dermatological complications vary from mild superadded bacterial infection to permanent scarring. Dermatoses such as psoriasis and lichen planus due to koebnerization may occur, as well. However a number of unrelated dermatological conditions like sarcoid granuloma, pseudolymphoma, xanthomas and epitheliomas have also been described in the literature.

We present a case of acneiform eruption following herpes zoster ophthalmicus, a very rare finding.

---

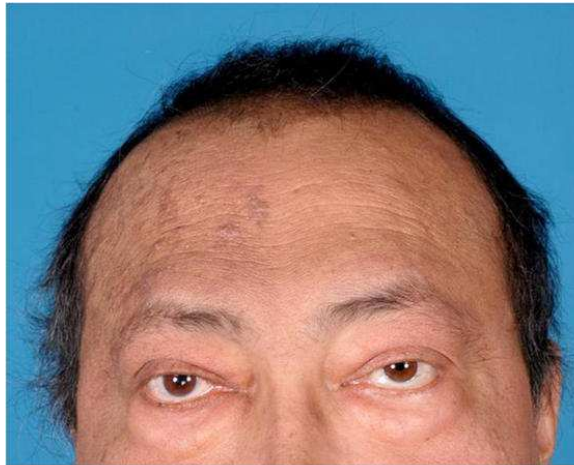**Address for correspondence**

Dr. Mansoor Haider,  
King Faisal Specialist Hospital and Research  
Centre  
Dermatology Unit, MBC 46-1  
P.O. Box 3354, Riyadh 11211  
Saudi Arabia  
Email: haidersm@yahoo.com

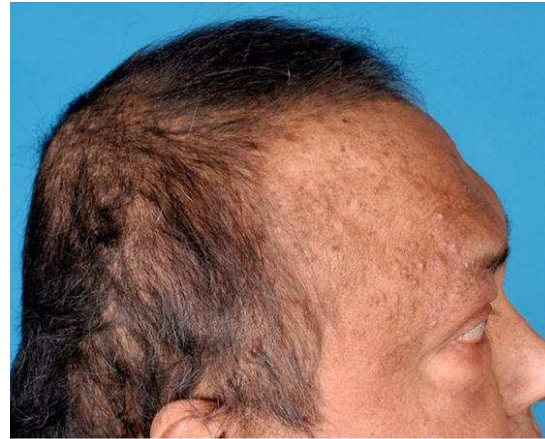
### Case report

A 48-year-old man, hypertensive, insulin-dependent diabetic with chronic renal failure, developed herpes zoster ophthalmicus on the right side which was confirmed by direct immunofluorescence and viral culture. In accordance with creatinine clearance, famciclovir 500 mg daily for seven days was started within 24 hours of the eruption along with analgesics and acyclovir 3% ophthalmic ointment for herpetic keratitis. Within 5-7 days the vesicles dried up followed by crusting and complete healing within two weeks without any residual pain.

Two months later he developed mild to moderate itching and irritation at the site of healed herpes zoster followed by an eruption after one week for which he had not used any topical or systemic treatment. On examination there were open comedones, erythematous papules and few pustules in the area of right ophthalmic division of trigeminal nerve, diagnosed as an acneiform eruption (**Figures 1 and 2**). He was treated with topical clindamycin phosphate 1% solution twice daily and adapalene gel 0.1% at night on the affected area. Itching and irritation abated within one month with complete clearing and only postinflamm-



**Figure 1** Acneiform eruption in right ophthalmic nerve distribution.



**Figure 2** Right lateral view of involved area.

**Table 1** Review of cases presenting as comedones or acneiform eruption following herpes zoster.

Sr. No.	Age/sex	Clinical presentation	Site	Year of case report	Reference No.
1.	18/Male	Comedones	Back	1916	10
2.	50/Male	Acneiform rash	Chest and axilla	1993	7
3.	50/Female	Comedones	Back	1997	1
4.	21/Male	Comedones	Back and arm	1997	1
5.	36/Female	Comedones	Frontal area	1997	1
6.	51/Female	Comedones	Back	1997	1
7.	44/Female	Comedones	Back	1997	1
8.	71/Female	Comedones	Back	1997	1
9.	65/Female	Comedones	Back	1997	1
10.	34/Male	Comedones	Neck and face	2007	9

atory pigmentation at two months.

## Discussion

Herpes zoster infection can be followed by several types of cutaneous reactions including comedones,<sup>1</sup> granuloma annulare,<sup>2</sup> sarcoidal granuloma,<sup>3</sup> pseudolymphoma,<sup>4</sup> squamous cell carcinoma,<sup>5</sup> basal cell carcinoma<sup>5</sup> and lichen planus.<sup>6</sup>

Occurrence of an acneiform eruption as an isotopic reaction at the site of herpes zoster is an unusual phenomenon, rarely described. Literature reviewed thoroughly from 1955 to 2009 revealed 9 cases of comedones and one case of acneiform eruption following herpes zoster<sup>1,7,8,9,10</sup> (Table 1). This is the second case report of acneiform eruption and the first at the

site of healed herpes zoster ophthalmicus.

Occurrence of a new unrelated disease at the site of previously healed skin disease is termed as "isotopic response".<sup>5,8</sup> Herpes zoster is the most common primary disease followed by herpes simplex and chicken pox. The interval between the primary and secondary disease may vary from days to years. In our case it was approximately eight weeks while similar cases ranged from few days to 8 months.<sup>7,9</sup>

An exact explanation for this phenomenon has not been so far established. Various hypotheses about the pathogenesis have been proposed including the possibility of viral, immunological, vascular and neural alteration.<sup>8</sup> The most plausible seems to be neural alteration followed by immunological dysfunction wherein

herpes zoster virus might cause damage of A $\delta$  and C fibers in the mid and lower dermis, resulting in the release of neuropeptides including substance P (SP). SP may stimulate lipogenesis of the sebaceous glands followed by proliferation of *Propionibacterium acnes*. SP also induces the expression of E-selectin by perisebaceous venules which stimulates mast cell-derived IL-6 and TNF- $\alpha$  which in turn induces nerve growth factor expression by the sebaceous cells.<sup>9</sup>

In our patient the concomitant occurrence of neurological symptoms in the form of itching and irritation along with the cutaneous eruption favors this hypothesis.

## References

1. Del Rio E, Allegue F, Vazques Veiga AH. Comedones appearing after herpes zoster infection: a report of 7 cases. *Arch Dermatol* 1997; **133**: 1316-7.
2. Ohata C, Shirabe H, Takagi K *et al*. Granuloma annulare in herpes zoster scars. *J Dermatol* 2000; **27**: 166-9.
3. Bisaccia E, Scarborough DA, Carr RD. Cutaneous sarcoid granuloma formation in herpes zoster scars. *Arch Dermatol* 1983; **119**: 788-9.
4. Roo E, Villegas C, Lopez-Bran E *et al*. Post zoster cutaneous pseudo lymphoma. *Arch Dermatol* 1994; **130**: 661-3.
5. Wolf R, Brenner S, Ruocco V, Filioli FG. Isotopic response. *Int J Dermatol* 1995; **34**: 341-8.
6. Strick S, Hyman AB. Lichen planus in the site of a previous zoster eruption. *Arch Dermatol* 1961; **84**: 509-10.
7. Stubbings JM, Goodfield MJD. An unusual distribution of an acneiform rash due to herpes zoster infection. *Clin Exp Dermatol* 1993; **18**: 92-3.
8. Ruocco V, Ruocco E, Ghersetich I *et al*. Isotopic response after herpes virus infection: An update. *J Am Acad Dermatol* 2002; **46**: 90-4.
9. Sardana K, Relhan V, Sehgal VN *et al*. Occurrence of acne comedones over healed linear scar of herpes zoster; a neurogenic perception. *JEADV* 2007; **21**: 431-2.
10. Blaschko A. Acne zosteriformis. *Arch Dermatol Syphilol* 1916; **123**: 242-51.

## ERRATUM

The following reference was missed in reference list of the editorial "*Dermatology: we need to look beyond the borders*" published in October-December, 2008 issue of *Journal of Pakistan Association of Dermatologists*.

1. Feldman SR. Looking beyond the borders of our specialty: the 2006 Clarence S. Livingood MD Lecture. *Dermatology Online J* 2007; **13** (4): 20.