

Short Communication

Fixed cutaneous sporotrichosis: a diagnostic challenge overcome by incidental discovery of asteroid bodies

Sir, sporotrichosis, a subcutaneous infection caused by the dimorphic fungus *Sporothrix schenckii*, has two major variants, the commoner lymphangitic form and the rarer but morphologically more variable fixed form.¹ Here we report a case of fixed sporotrichosis where atypical morphology and absence of fungal growth in culture presented a considerable diagnostic difficulty.

A 40-year-old lady came to our hospital with single 3.5cm x 2.5cm erythematous ulcerated plaque over her right forearm for 3 years (**Figure 1**). The surface of the lesion was crusted at most parts. On palpation the plaque was mildly tender. Patient had history of intermittent purulent discharges from the lesion. Though she had worked in the fields and garden for many years, no specific history of prick or local trauma could be elicited. No significant lymphadenopathy could be detected. Initially our clinical differentials included lupus vulgaris and atypical mycobacterial infection.

Complete blood count and all other routine baseline parameters did not reveal any abnormality. Mantoux test showed 4mm induration with 5 TU. Fungal culture report was negative. Ziehl-Neelsen staining and mycobacterial culture turned up negative for acid-fast bacilli.

Skin biopsy for histopathology showed neutrophilic abscess in the deep dermis surrounded by mixed inflammatory infiltrate

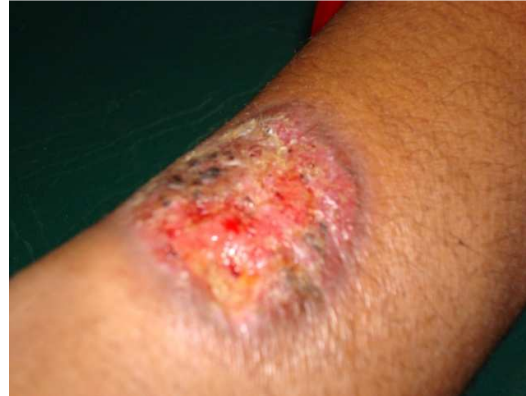

Figure 1 Ulcerated and crusted plaque in right forearm.

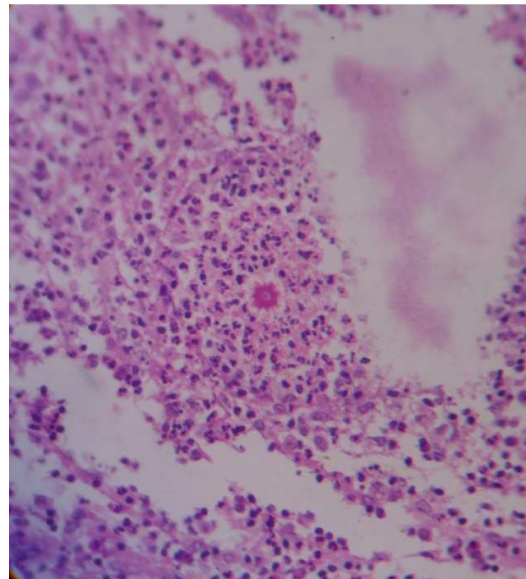


Figure 2 Asteroid body surrounded by a mixed infiltration of inflammatory cells.

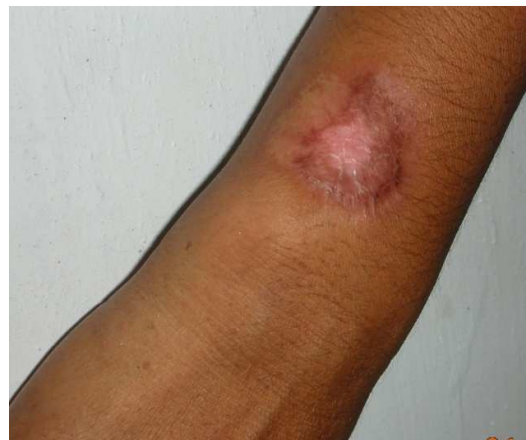

Figure 3 lesion completely healed with scarring.

composed of lymphoid cells, eosinophils, plasma cells and epithelioid cells. However, in careful inspection we could find a few asteroid bodies in couple of fields. (Figure 2). We made a working diagnosis of sporotrichosis and a therapeutic trial with saturated solution of potassium iodide (SSKI) was started as an in-patient basis. The initial dose was 5 drops three times daily which was gradually increased to 15 drops three times daily. Patient started showing improvement and after 4 weeks her lesion healed completely with mild scarring (Figure 3). She tolerated the medication well which was gradually tapered of it in another month. She was closely followed up for 4 months and did not show any sign of recurrence.

Sporotrichosis occurs both in temperate and tropical countries. The fungus grows on decaying vegetable matter. Mine workers may harbor the fungus without having sporotrichosis.² The disease may occur in other groups occupationally exposed to the organism, such as workers using straw as packing material, forestry workers, florists or gardeners.³ In most cases of cutaneous sporotrichosis, the fungus is introduced into the skin through a local injury and in the fixed variety the pathogen remains localized at the point of inoculation.⁴

Lymphocutaneous sporotrichosis accounts for almost 70% of the cases of sporotrichosis.⁵ This variety of sporotrichosis presents a distinctive clinical picture, with nodules and ulcers arranged linearly along the lymphatics with thickened lymphatic cords between the nodules, usually on exposed skin.⁶ Fixed form occurs in about 15% cases and may be acneiform, nodular, ulcerated, verrucous, infiltrated plaques or red scaly patches. Contrary to other clinical forms, the localized form is associated with a high host-resistance wherein the sporotrichin test is positive, spontaneous resolution is not uncommon and

response to SSKI is better. These characteristics suggest an immunological spectrum for the disease-fixed cutaneous sporotrichosis with a well-developed immune response at one end, lymphocutaneous and disseminated forms with poorly developed immune response at the other end of the spectrum.⁵ The fixed cutaneous type is more difficult to diagnose and may be mistaken for other causes of a persistent, non-healing ulcer or nodule, chiefly tuberculosis⁷ and atypical mycobacteria.⁸

In our patient the diagnosis of sporotrichosis was extremely difficult because of atypical clinical presentation and negative fungal culture. However, an incidental finding of asteroid body in biopsy gave us an important diagnostic clue. Though asteroid body can be found in other infective and granulomatous conditions including sarcoidosis, a provisional diagnosis of fixed cutaneous sporotrichosis was made on clinicopathological correlation. A trial of SSKI confirmed the diagnosis as the lesion completely healed with minimal scarring.

References


1. Agarwal S, Gopal K, Umesh, Kumar B. Sporotrichosis in Uttarakhand (India): a report of nine cases. *Int J Dermatol* 2008; **47**: 367-71.
2. Hay RJ, Moore N.K. Mycology. In: Burns T, Breathnach S, Cox N, Griffiths C, editors. *Rook's Textbook of Dermatology, Vol 2, 7th edition*. Carlton, Australia: Blackwell; 2004. P. 31.76-78.
3. Werner AH, Werner BE. Sporotrichosis in man and animal. *Int J Dermatol* 1994; **33**: 692-700.
4. Hemashettar BM, Kuchabal DS, Hanchinamani Suman P. Fixed cutaneous sporotrichosis from North Karnataka. *Indian J Dermatol Venereol Leprol* 1992; **58**: 45-7.
5. Goncalves AP. Sporotrichosis. In: Canizares O, Harman R, editors. *Clinical Tropical Dermatology, 2nd edn*. Philadelphia: Blackwell Scientific Publications; 1992. p. 88-93.

6. Itoh M, Okamoto S, Kanya S. Survey of 260 cases of sporotrichosis. *Dermatologica* 1986; **172**: 203-13.
7. Sperling LC, Read SI. Localized cutaneous sporotrichosis. *Int J Dermatol* 1983; **22**: 525-8.
8. Patel AB, Shaikh S. Fixed cutaneous sporotrichosis. *Indian Pediatr* 2006; **43**: 73-4.

Abanti Saha, Abhishek De, Pijush Kanti Datta, Nilay Kanti Das
Department of Dermatology, Medical College, Kolkata, India

Address for Corresponding

Dr. Abhishek De,
Flat number C 14, 87B Cossipore Road,
Kolkata 700002, India.
E-mail: dr_abhishek_de@yahoo.co.in



The theme of the conference is
“Practical Dermatology”
and we wish to offer you a very PRACTICAL and INTERACTIVE academic moot where most of the presentations will effectively correspond to an application in your daily practice. The conference, thus, is the one not to be missed. Come and benefit from the wisdom and experience of international-class speakers and presenters.

Prof. Shahid Javaid Akhtar
Department of Dermatology
PMC/DHQ Hospital, Faisalabad
www.PAD2010.com