

# Review Article

## Pathogenesis of acne vulgaris: simplified

Ch. Muhammad Tahir

Consultant Dermatologist, WAPDA Hospital Complex, Lahore.

**Abstract** Acne vulgaris is a common chronic inflammatory disease of the pilosebaceous unit. It is characterized by the formation of non-inflammatory comedones and inflammatory papules, pustules, nodules and cysts. Acne is extremely common and usually starts during the teenage years but can start for the first time in their 20s and 30s. The lesions usually involve the face, back and chest. Severe inflammation may lead to scarring after healing. Psychosocial impact of acne can be tremendous and lead to a poorer quality of life. Proper understanding of pathogenesis of acne will lead to better management.

**Key words**

Acne vulgaris, pathogenesis, *Propionibacterium acnes*.

### Introduction

Acne vulgaris is a disease of pilosebaceous unit characterized by the formation of open and closed comedones, papules, pustules, nodules and cysts. It is the most common disorder treated by dermatologists.<sup>1</sup>

The term acne is derived from Greek word “acme” which means “prime of life”. Although generally considered to be a benign, self limiting condition, acne may cause severe psychological problems or disfiguring scars that can persist for a lifetime.<sup>2</sup>

It is a pleomorphic disorder and can manifest at any time during life<sup>3</sup> but it most commonly presents between ages of 12-24, which estimates of 85% of population affected.<sup>3</sup> In recent years multifactorial nature of acne has been elucidated. An improved understanding of the pathophysiology of acne leads to rational therapy for successful treatment.<sup>4</sup>

---

**Address for correspondence**

Dr. Ch. Muhammad Tahir,  
Consultant Dermatologist  
WAPDA Medical Complex,  
Ferozpur Road, Lahore  
Email: drtahirchskin@hotmail.com

### Pathogenesis of acne vulgaris

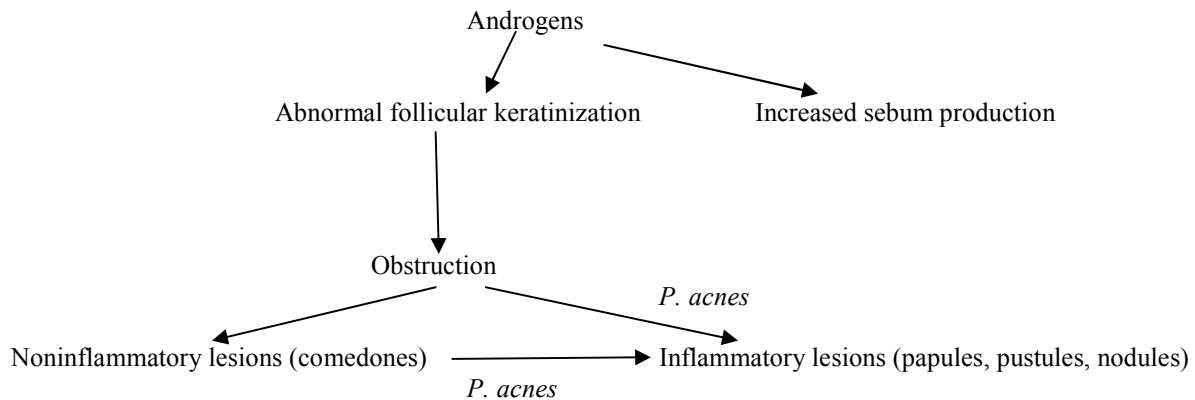
The precise mechanisms of acne are not known but there are four major pathogenic factors<sup>5</sup>: 1. increased sebum production; 2. hypercornification of pilosebaceous duct, 3. abnormal bacterial function; and 4. production of inflammation (**Figures 1 and 2**).

#### **1. Increased sebum production**

Role of sebaceous glands in the pathogenesis of acne has long been recognized, so much so that the disease is standardly classified as a sebaceous gland disorder. However, such a designation is oversimplification.<sup>6</sup>

Pilosebaceous unit, the ‘seat’ of acne, is cell lined follicle with large sebaceous gland and a fine vellus hair that rarely extends out of follicle. These are most common in the acne prone areas such as cheek, nose and forehead and also on the chest and back.<sup>4</sup>

Increased rate of sebum production is one of the most important factors involved in the development of acne lesions. As a group, patients with acne secrete more sebum than normal individuals and severity of acne is



**Figure 1** Basic mechanisms involved in the pathogenesis of acne.

related to the degree of seborrhea which is directly dependant on the size and rate of growth of sebaceous glands, which is under the control of androgens.<sup>7</sup>

Elevated serum levels of free testosterone were noted in acne patients, which correlated with acne lesions. Free testosterone is the only parameter which may be used diagnostically in males. A positive correlation exists between androgens and acne lesions in males. A positive correlation between androgens and acne lesions in females points to the importance of peripheral hormone action in the skin.<sup>8</sup>

Increased sebum production characteristic of patients with acne is often due to end-organ hyper response.<sup>5</sup> Differential peripheral conversion of testosterone to dihydrotestosterone may explain why glands in sebaceous areas enlarge at puberty. Plasma testosterone levels are usually elevated in females with nodulocystic acne.<sup>1</sup>

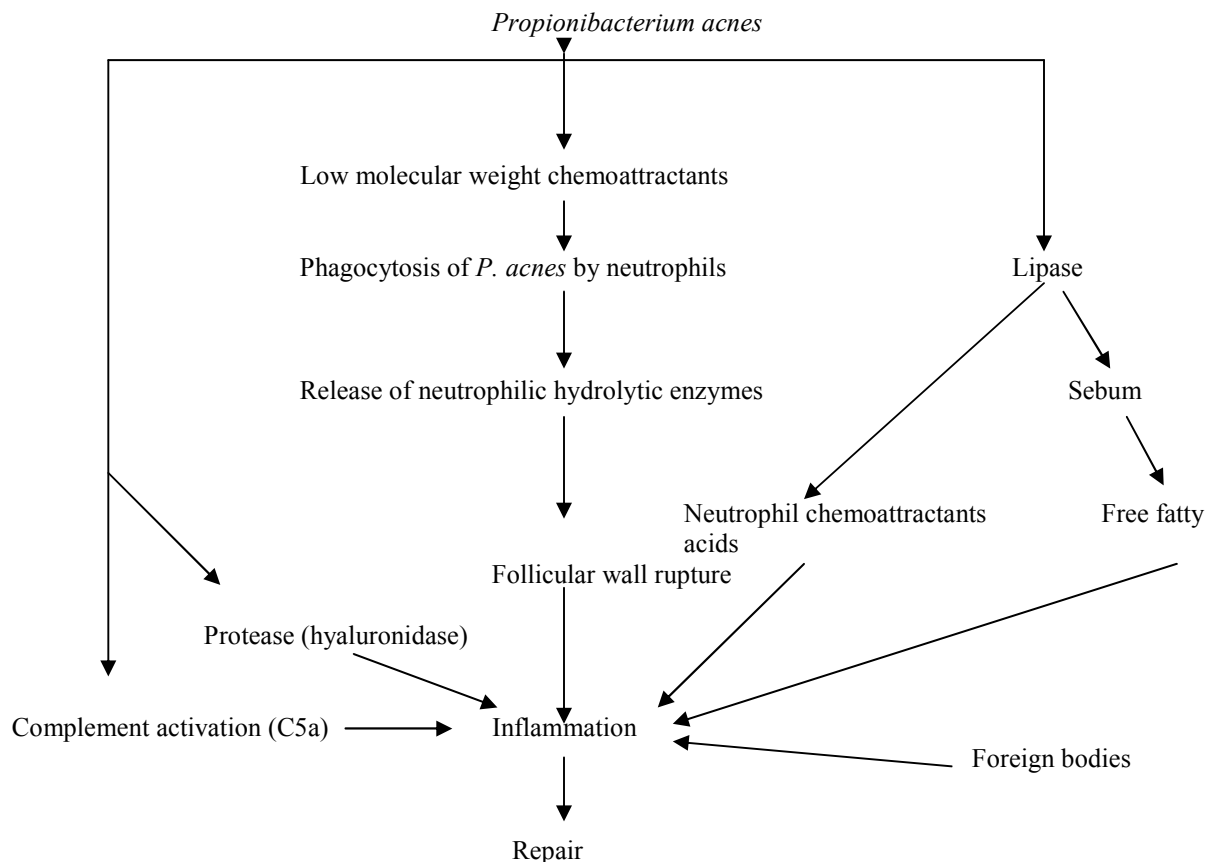
One possible role of sebum in the pathogenesis of acne is its primary or associative role in comedogenesis.<sup>6</sup> Another indisputable role for sebum is providing the substrate for *P. acnes* growth, specifically triglyceride acted upon by

*P. acnes* lipase to form diglycerides, *P. acnes* lipase to form diglycerides, monoglycerides and free fatty acids from which glycerol, the utilizable moiety for *P. acnes* metabolism is formed.<sup>9</sup>

## 2. **Hypercornification of the pilosebaceous duct**

Obstruction of the pilosebaceous canal precedes the development of acne lesions. The obstruction is produced by the accumulation of adherent keratinized cells within the canal that form an impaction obstructing the flow of sebum. Cause is unknown but the process may be under the influence of androgens.<sup>2</sup> It may also be due to an abnormality in the sebaceous lipids resulting in a relative hyperproliferation of corneocytes.<sup>8</sup> Comedone formation may be due to a localized deficiency of linoleic acid in pilosebaceous duct. Linoleic acid is incorporated via plasma into sebaceous gland cells, where it is diluted due to large volume of sebum and the ductal corneocytes are effectively bathed in an inadequately low level of linoleic acid.<sup>5</sup>

As the follicular lumen becomes obstructed by abnormally desquamated follicular cells, sebum gets trapped behind the hyperkeratotic plugs, dilating the follicle. Normal follicular architecture is lost at this point.<sup>4</sup>The end result



**Figure 2** Sequence of events leading to acne inflammation primarily induced by *P. acnes* [6].

of this hyperkeratinization is the development of a comedo (pl. comedones) {open comedone = blackhead and closed comedone = whitehead}. Microscopically these lesions are dilated pilosebaceous ducts containing a mixture of cornified follicular epithelium, sebum, bacteria and saprophytic yeasts.<sup>7</sup>

Premenstrual exacerbation of acne, a well recognized clinical feature, can also be explained to some extent by changes in duct size as fluid retention swells keratin.

Biopsy and culture of early non-inflamed lesions show that 30% of these are without bacteria<sup>10</sup> suggesting that ductal bacteria are not needed for initiation of cornification.

Prime defect in acne vulgaris is an increase in sebum excretion, which in turn leads to bacterial colonization and infection, which in turn causes histopathological (and clinical) lesions of acne – a minor component of which is the ductal changes. Ductal blockage theory is a myth that persists in the face of all evidence that suggests the changes interpreted as blockage are secondary. In particular, there is no evidence that comedones are primary lesions and the black headed ones are innocent bystanders on the pathological primrose-path to papules and pustules.<sup>8</sup>

### 3. **Abnormal bacterial function**

Have follicular micro-organisms a role in acne? The answer to this question with present knowledge is both yes and no. A role of microorganisms in acne has been championed

since the beginning of the 20<sup>th</sup> century. Skin surface in acne prone areas are colonized with *Staphylococcus epidermidis* and *Propionibacterium acnes*. Selective inhibitory studies suggest that the main organism is *P. acnes*.<sup>5,16</sup>

The anaerobic *P. acnes* proliferates in the ideal environment of the comedo: an obstructed lipid rich lumen with decreased oxygen tension.<sup>4</sup> This overgrowth of *P. acnes* hydrolyses sebum triglycerides, producing free fatty acids which may lead to microcomedo formation.<sup>11</sup>

At present it is not possible to decide whether the microflora are initiators of the lesions or whether they take advantage of the habitat in the lesion, or whether a critical balance of groups of micro-organisms occupying a follicle is the essential factor for the acnegenesis.<sup>5</sup>

#### 4. Production of inflammation

The association of *P. acnes* proliferation with inflammatory lesions of acne is best borne out with the significant suppression of *P. acnes* with antibiotic therapy. There is a parallel improvement and decrease in the number of acne lesions. *P. acnes* contributes to inflammation through activation of various chemotactic factors, as well as, through promoting rupture of the comedo.<sup>4</sup>

It is not clear why the endogenous bacteria colonize the sebaceous follicles. *P. acnes* elaborate a low molecular weight polypeptide<sup>12</sup> that presumably diffuses through abnormally keratinized follicular epithelium of sebaceous follicles, still physically intact and attract polymorphonuclear leucocytes to follicular site. The intrafollicular *P. acnes* is ingested by neutrophil, with the consequent release of hydrolytic enzymes that are thought to effect follicular wall dyshesion and rupture. This

disruption allows the intrafollicular contents to escape into surrounding dermis and produce inflammation. Experimental evidence suggests that inflammation results from a variety of insults, such as neutrophilic hydrolytic enzymes, *P. acnes* enzymes, sebum and foreign bodies (Figure 2).<sup>6</sup> The combination of keratin, sebum and microorganism particularly *P. acnes* leads to release of proinflammatory mediators and accumulation of T-helper lymphocytes, neutrophils and foreign body giant cells. This in turn causes the formation of inflammatory papules, pustules and nodulocystic lesions.

Early cellular infiltrate is lymphocytic seen around blood vessels and duct. Within 12-24 hours polymorphonuclear leucocytes appear but lymphocytes remain in the papule as predominant cell infiltrate. Ductal rupture is not a prerequisite for development of inflammation.

The impact of emotional well being and function can be critical and is associated with depression and higher than average unemployment rates.<sup>14,15</sup> Proper understanding of pathogenesis of acne will lead to successful acne management which necessitates the ability of treating physician to apply therapy to evolutionary stage of disease. More than one pathogenic mechanism should be targeted for treating acne lesions.

#### References

1. Sams WM Jr, Lynch PJ, eds. *Principles and Practice of Dermatology*. New York: Churchill Livingstone; 1990.
2. Leung AK, Robson WL. Acne. *J R Soc Health* 1991; **111**: 57-60.
3. Winston MH, Shalita AR. Acne vulgaris – pathogenesis and treatment. *Pediatr Clin North Am* 1991; **38**: 889-903.
4. Eichenfield LF, Leyden JJ. Acne: Current concepts of pathogenesis and approach to

- rational treatment. *Paediatrician* 1991; **18**: 218-23.
5. Cunliffe WJ, Marks R, eds. *Acne*. London: Martin Dunitz; 1989.
  6. Pochi PE, The pathogenesis and treatment of acne. *Ann Rev Med* 1990; **41**: 187-98.
  7. Lever I, Marks R. Current views on aetiology, pathogenesis and treatment of acne vulgaris. *Drugs* 1990; **39**: 681-92.
  8. Schmidt JB, Spona J, Niebauer G. Endocrinological involvement in acne. In: Marks R, Plewing G, eds. *Acne and Related Disorder*. London: Taylor & Francis; 1989. P. \*\*
  9. Rebello TJ, Hawk LM. Skin surface glycerol levels in acne vulgaris. *J Invest Dermatol* 1978; **70**: 353-4.
  10. Leeming JP, Holland KT, Cunliffe WJ. The pathogenesis and ecological significance of microorganisms colonizing acne vulgaris comedone. *J Med Microbiol* 1985; **20**: 11-6.
  11. Downing DT, Stewart ME, Wertz PW *et al*. Essential fatty acids and acne. *J Am Acad Dermatol* 1986; **14**: 221-5.
  12. Puhrel SM, Sakamoto M. The chemoattractant properties of comedonal contents. *J Invest Dermatol* 1978; **70**: 353-4.
  13. Bergfeld WF. Topical retinoids in management of acne vulgaris. *J Drug Dev Clin Pract* 1996; **8**: 151-60.
  14. Asad F, Qadir A, Ahmad L. Anxiety and depression in patients with acne vulgaris. *J Pak Assoc Dermatol* 2002; **12**: 69-72.
  15. Katsambas AD, Stefanaki C, Cunliffe WJ. Guidelines for treating acne. *Clin Dermatol* 2004; **22**: 439-44.
  16. Joo SS, Jang SK, Kim SG *et al*. Anti-acne activity of *Selaginella involvens* extract and its non antibiotic anti-microbial potential on *Propionibacterium acnes*. *Phytother Res* 2008; **22**: 335-9.

### **Manuscript Submission**

Manuscripts may be emailed to the Editor,

Prof. Dr. Ijaz Hussain,

E mail: [drijazhussain@gmail.com](mailto:drijazhussain@gmail.com).