

Case Report

Disseminated superficial actinic porokeratosis

Sanjiv V Choudhary*, Navrajsingh Virk*, Sankha Koley**, Gunjan Nitnavare*

* Department of Dermatology, J.N.Medical College, Sawangi, Wardha [M.S], India.

** Department of Dermatology, B.S Medical College, Bankura, India

Abstract

A 45-year-old male patient, farmer by occupation, presented with multiple disseminated, light brown-colored, annular plaques with a raised hyperkeratotic ridge-like border with atrophic center distributed over sun exposed parts like V-area of neck, upper chest, extensor aspect of upper extremity. A thin furrow was typically seen in the center of the keratotic ridge of the lesions. There was no family history of similar lesions. Histopathological examination of the skin biopsy taken from the ridge of the lesions showed histopathological hallmark of porokeratosis the 'cornoid lamella'. We report a sporadic case of disseminated superficial actinic porokeratosis in dark-skinned male patient.

Key words

Disseminated superficial actinic porokeratosis.

Introduction

The lesions of classical porokeratosis were described by Mibelli in 1893. In 1966 disseminated superficial actinic porokeratosis (DSAP) was described by Cherosky. Porokeratosis is an inherited disorder of keratinization characterized clinically by skin lesions with distinctive hyperkeratotic ridge-like border and histologically by presence of cornoid lamella. The parakeratosis appears to be the result of faulty maturation of keratinocytes, rather than an increased rate of proliferation.¹ Five clinical variants of porokeratosis are recognized: classic porokeratosis of Mibelli (PM), disseminated superficial actinic porokeratosis (DSAP), porokeratosis palmaris et plantaris disseminata (PPPD), linear porokeratosis, and punctate porokeratosis. Several other variants have been described.

Several risk factors for the development of porokeratosis have been identified; these factors include genetic inheritance, ultraviolet radiation, and immunosuppression. Sun exposure and/or artificial ultraviolet radiation exposure in a patient who is genetically predisposed causes DSAP. The formation of squamous or basal cell carcinomas has been reported in all forms of porokeratosis.^{2,3,4}

Protection from the sun, use of emollients, and watchful observation for signs of malignant degeneration may be all that is needed. Several medications have potential benefit like topical 5-fluorouracil, topical vitamin D analogues, topical immunomodulators like 5% imiquimod, systemic retinoids, photodynamic therapy, cryotherapy, electrodesiccation and curettage, CO₂ laser and pulsed dye laser and surgical excision for lesions showing malignant changes.

Address for correspondence

Dr. Sanjiv V. Choudhary,
Associate Professor,
Department of Dermatology,
J.N.Medical College, Sawangi, Wardha [M.S],
India
E mail: sanjiv_choudhary26@yahoo.com

Case report

A 45-year-old male patient farmer by occupation presented with mildly itchy, multiple, small, light brown skin lesion over sun exposed parts

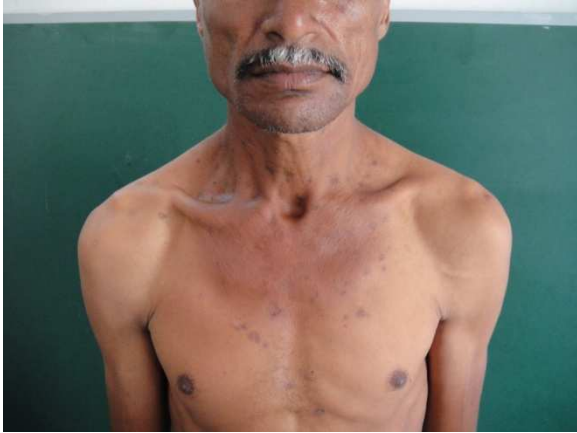

Figure 1 Lesions of disseminated superficial actinic porokeratosis over chest and neck.

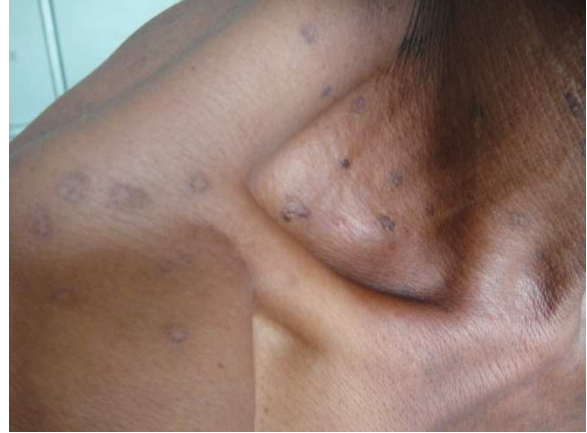

Figure 2 Lesions of disseminated superficial actinic porokeratosis over neck and shoulder.

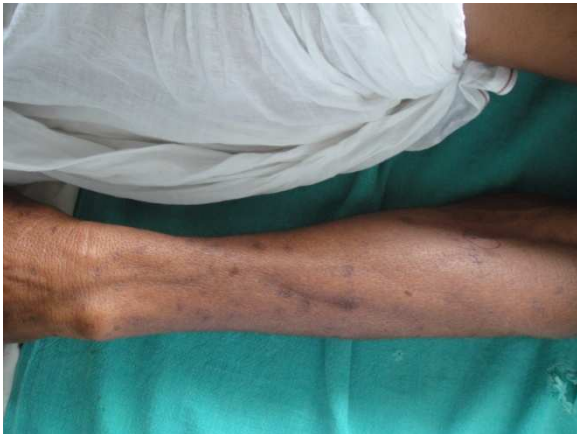

Figure 3 Lesions of disseminated superficial actinic porokeratosis over dorsum of forearm.

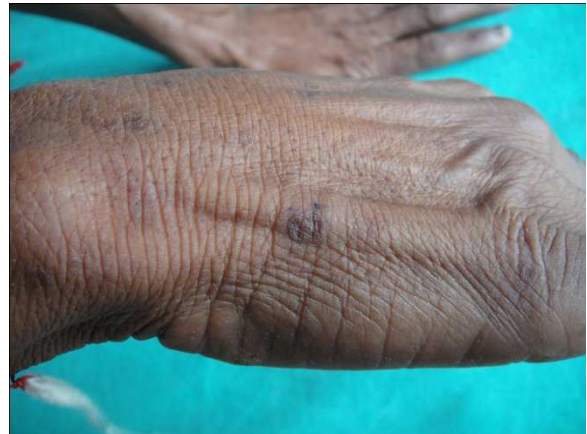

Figure 4 Classical lesion of disseminated superficial actinic porokeratosis showing hyperkeratotic ridge with furrow and central atrophy over dorsum of hand.

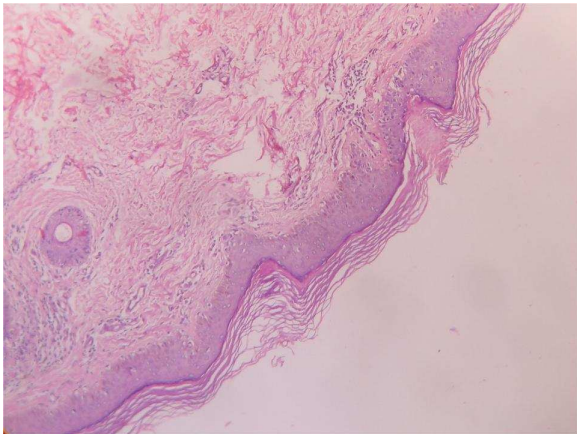


Figure 5 Column of tightly packed parakeratotic cells within a keratin-filled epidermal invagination i.e. the cornoid lamella (10 X).

of body keratotic since past 4 years. History of photosensitivity was present. There was no history of similar lesions in any other family

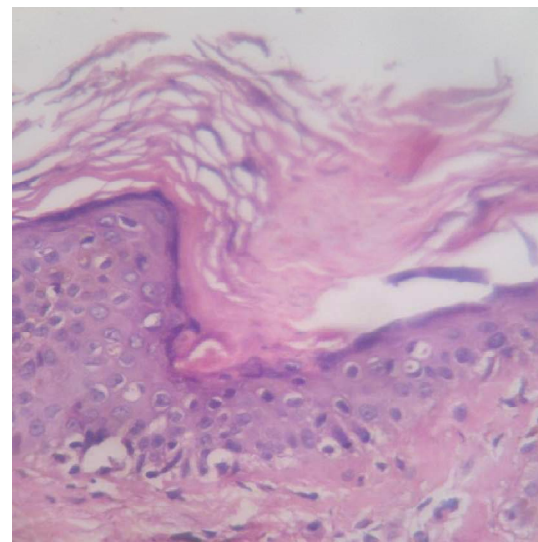


Figure 6 Cornoid lamella (40 X).

member. Cutaneous examination revealed multiple, light brown colored, annular plaques with a raised hyperkeratotic ridge-like border with atrophic center distributed over sun exposed part like V-area of neck, upper chest, extensor aspect of upper extremity (**Figures 1-3**). A thin furrow was typically seen in the center of the keratotic ridge of the lesions (**Figure 4**). Routine laboratory investigations along with blood sugar levels were normal. Blood for anti-HIV antibodies was negative. Histopathology of skin biopsy taken from the raised hyperkeratotic ridge of the skin lesion, revealed column of tightly packed parakeratotic cells within a keratin-filled epidermal invagination i.e. the cornoid lamella, absence of granular layer below the cornoid lamella and nonspecific dermal inflammatory infiltrate (**Figures 5 and 6**). With this history, clinical examination and histopathological findings diagnosis of disseminated superficial actinic porokeratosis was made. The patient was given topical sunscreen during day time and topical 5-fluorouracil at night time. Patient was called for follow-up after three weeks.

Discussion

The disease is common between 2nd to 4th decades, transmitted in an autosomal dominant fashion, and is more frequent in women.⁵ Though, porokeratosis is a known autosomal dominant genodermatosis, sporadic cases also occur. All the three cases reported by Rama Rao *et al.*⁶ in the literature were sporadic ones without any family background.

The skin lesions of disseminated superficial actinic porokeratosis are most pronounced on sun exposed areas and may aggravate after sun exposure.⁷ Histopathologically it is characterized by the presence of cornoid lamella.⁸

Our male patient was in 4th decade of life. He was farmer by occupation and used to work 4 to 6 hours daily in intense sunlight. He had history of photosensitivity and classical skin lesions with hyperkeratotic ridge with central atrophy mainly distributed over sun exposed parts of the body. No other family members had similar skin lesions. Our patient had dark complexion. Histopathological examination of the skin biopsy taken from the ridge of the lesions showed histopathological hallmark of porokeratosis the, 'cornoid lamella'.

We report a sporadic case of disseminated superficial actinic porokeratosis in dark skinned male patient.

References

1. Fernandez-Flores A. Small lesions of porokeratosis show a normal proliferation rate with MIB-1. *Acta Dermatovenerol Alp Panonica Adriat* 2008; **17**: 22-5.
2. James WD, Rodman OG. Squamous cell carcinoma arising in porokeratosis of Mibelli. *Int J Dermatol* 1986; **25**: 389-91.
3. Sasson M, Krain AD. Porokeratosis and cutaneous malignancy. A review. *Dermatol Surg* 1996; **22**: 339-42.
4. Seishima M, Izumi T, Oyama Z, Maeda M. Squamous cell carcinoma arising from lesions of porokeratosis palmaris et plantaris disseminata. *Eur J Dermatol* 2000; **10**: 478-80.
5. Arnold HL, Odom RB, James WD, editors. *Some Genodermatosis*. Philadelphia: Saunders, 1990: 668.
6. Rama Rao RG, Sundareswar B, Reddy PP *et al.* Porokeratosis - report of three unusual cases. *Indian J Dermatol Venereol Leprol* 1998; **64**: 286-8.
7. Lever WF, Schaumburg-Lever G, editors. *Histopathology of Skin*. Philadelphia: JB Lippincott; 1992. P. 70-1.
8. O'Regan GM, Alan D. Irvine AD. Porokeratosis, In: Wolff K, Goldsmith LA, Katz SI *et al.*, editors. *Fitzpatrick's Dermatology in General Medicine*, 5th edn. Philadelphia: McGraw-Hill; 1999. P. 442-6.