

Original Article

Direct immunofluorescence and histopathology in chronic discoid lupus erythematosus

Shahzana Naqqash, Faria Asad*, Sabrina Suhail Pal*

Department of Dermatology, Services Institute of Medical Sciences, Services Hospital, Lahore

*Department of Dermatology, KEMU, Mayo Hospital, Lahore.

Abstract *Background* Lesions of chronic discoid lupus erythematosus (DLE) are characterized by sharply demarcated, scaly, infiltrated and later atrophic red discoid plaques. They have pathognomonic histological features, helping in confirmation of the diagnosis. Since the introduction of direct immunofluorescence, the lupus band test has become an important tool for the diagnosis of cutaneous lupus erythematosus.

Objective To elaborate the specific histopathological features and direct immunofluorescence findings in the lesions of chronic discoid lupus erythematosus.

Patients and methods Patients of any age and either sex presenting with clinically suggestive lesions of discoid lupus erythematosus, attending the outpatient dermatology department of Mayo Hospital were enrolled. The biopsy specimens of the lesional skin were bisected and subjected to histopathology and direct immunofluorescence.

Results Out of 29 patients, the diagnostic histopathological features were found in 23 (79.9%) patients, in 5 (16%) the changes were suggestive. We could not reach to a diagnosis in one patient. Diagnostic lupus band was found in 20 (68.5%), while fluorescence at dermoepidermal junction was suggestive of lupus band in 3 (11%). No fluorescence was observed in 6 (20.5%). A combination of the two techniques gave better results 85%.

Conclusion Direct immunofluorescence is a useful technique in the diagnosis of discoid lupus erythematosus; however, it should be used in conjunction with haematoxylin and eosin-stained sections.

Key words

Discoid lupus erythematosus, histopathology, direct immunofluorescence.

Introduction

Cutaneous lesions occur in majority of lupus patients and constitute four of the 11 American Rheumatism Association (ARA) criteria for diagnosis of systemic lupus erythematosus (SLE) i.e. discoid lesions, malar rash, photosensitivity and oral ulcers.¹ The discoid lesions are characterized by sharply-

marginated, scaly, infiltrated and later atrophic red discoid plaques, usually occurring on sun exposed areas.² They have well-defined pathognomonic histological features, which help in confirming the diagnosis of chronic discoid erythematosus in majority of the patients.³ The principal immunologic finding of clinical relevance in cutaneous lupus erythematosus (LE) is the presence of immune deposits at dermoepidermal junction (DEJ) of the lesional skin i.e. the lupus band test (LBT). Since the introduction of direct immunofluorescence (DIF) method for the detection of immune deposits in LE by

Address for correspondence

Dr. Shahzana Naqqash, Assistant Professor,
Services Institute of Medical Sciences, Services
Hospital, Lahore.

Ph: *923334713033

E mail: dr_shahzana_naqqash@gmail.com

Burnham *et al.*^{4,5} and Cormane,⁶ the LBT has been proved to be an important tool for diagnosis of cutaneous lupus erythematosus.

We carried out this study to document the distinct histopathological features and direct immunofluorescent findings in the lesions of chronic discoid lupus erythematosus (CDLE).

Patients and methods

The study was conducted at the dermatology department of King Edward Medical University/Mayo Hospital, Lahore. Patients of any age and either sex who had clinically suggestive lesions of chronic discoid lupus erythematosus were enrolled. An informed consent was taken from every patient. After thorough history and detailed clinical examination, an elliptical biopsy from an active lesion was taken. The specimen was bisected, one half was formalin fixed, embedded in paraffin and examined after hematoxylin and eosin staining (HE staining) under the light microscope. The other half was snap frozen in liquid nitrogen. The 5 µm sections were subjected to DIF technique for IgG, IgM, IgA and C3 with antibodies labelled with fluorescein. The slides were examined under ultraviolet microscope.

Histopathological diagnostic criteria

The histopathological diagnosis was based on the characteristic features as described by Lever and Schaumberg-Lever.⁷ A definitive diagnosis of CDLE was made when at least 2 of the three pathognomonic features were present i.e. 1) liquefaction degeneration of basal cell layer, 2) fibrinoid changes in dermal collagen, most marked below the epidermis, and 3) patchy dermal mononuclear infiltrate (particularly periadnexal).

The diagnosis was suggestive when one of the diagnostic features along with other

histopathological changes was seen i.e. 1) hyperkeratosis, 2) follicular plugging, 3) epidermal thinning, and 4) pilosebaceous atrophy

Diagnostic criteria for immunofluorescence

For a positive diagnosis of DLE, a strongly positive, sharply-demarcated, brightly fluorescent apple-green band at basement membrane zone (BMZ) with antisera against IgG and/or IgM along with C3 was required, in a granular band-like or homogenous pattern. Possible DLE was diagnosed, when the band-like staining was weakly positive or moderate amounts of IgM and complement, without IgG were present in a granular pattern. The diagnosis was negative or nonspecific, when only complement was found.

Results

Demographic data

Out of 29 patients, there were 22 females. The age of onset of the disease was 14-60 years while the duration varied between 8 weeks to 20 years. Most of the lesions were present on sun-exposed areas, only a few had lesions on their covered parts, as well. Almost half the patients had mucous membrane involvement.

Histopathological findings

The pathognomonic histopathological changes were present in 23 (79.7%) of patients (**Figures 1**), while in 5 (16%) the changes were suggestive. We could not reach to a diagnosis in one patient.

Findings of direct immunofluorescence

Direct immunofluorescence findings were diagnostic (**Figure 2**) in 20 (68.5%), while fluorescence at dermoepidermal junction was suggestive of lupus band in 3 (11%). No

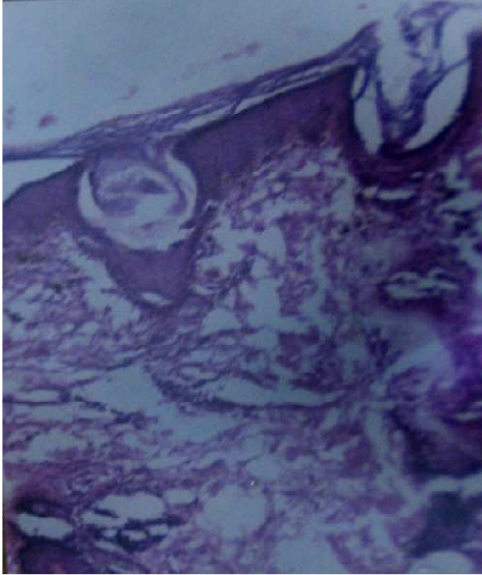


Figure 1 Characteristic histopathology of DLE lesion.

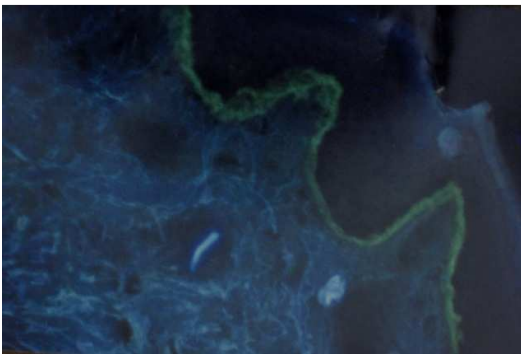


Figure 2 Lupus band at dermoepidermal junction with anti-IgG (lesional skin).

immunofluorescence was observed in 6 (20.5%). IgG alone was demonstrated in 17.4% and IgM was present in 4.3%. In the rest of the cases, they were found in combination with other immunoreactants. IgG was seen in 74% of cases, IgM in 61%, IgA in 26% and complement in 52% of cases. Complement was always found in association with one or other antibodies.

Discussion

The histopathological and DIF results of our study are in accordance with other studies.⁸ Although, the histopathology showed more positive results (79.7%) than DIF (68.5%), the difference was not statistically significant; a

combination of the two techniques gave better results (85%). These results are comparable to the findings by Al-Swaid *et al.*⁸

The presence of immunoreactants at the DEJ of patients with DLE is characteristic, and the presence of a band of deposited IgG, IgM, IgA, and/or C3 is widely used to diagnose these lesions. However, one must consider the types of immunoreactants, the intensity of staining, and the quality of the band, as mere presence or absence of immunoreactants at the DEJ is not that helpful.

The initial studies by Tuffanelli⁹ showed positivity in more than 90% cases; however, the most recent studies have shown lower frequencies of positive results. These recent reports and our lower results are due to the strict diagnostic criteria adopted for lupus band test.

The other factors which can affect the quality of lupus band are duration and distribution of lesions, amount of sun exposure, prior steroid therapy, type of lesion etc.¹⁰ Some studies demonstrated that lesions with duration of less than 3 months may not reveal immunoglobulin or complement deposition at DEJ.¹¹ This parameter could not be defined in our study because we could not specify the duration of the lesions on which biopsies were performed, but only the duration the disease. Likewise the influence of prior treatment with corticosteroids could not be analyzed because of the unreliable history and non compliance of the majority of the patients.

Most biopsied lesions in our study were located in sun-exposed areas; a fact that undoubtedly accounts for the great number of positive results by other researchers.^{12,13} Cases in which the biopsy was obtained from unexposed areas were few; therefore, this was not the determining factor for the smaller

number of positive results in this study as compared with previous data.

The most common immunoreactant was IgG at the DEJ, followed by IgM and IgA; this agrees with other reports.¹⁴ The frequency of different immunoreactants and the morphological patterns observed in our study are in accordance with the observations made by others.⁸

The comparison of the two diagnostic techniques showed that the sensitivity of DIF is not significantly greater than that of histopathology. On the other hand, histopathology gave positive or suggestive results in almost all the cases, in contrast to DIF that gave negative results in 4 patients. A combination of the two techniques yielded more reliable results than either technique alone. This is similar to the study by Nieboer.¹²

The real advantage DIF lay in the additional diagnostic value it provided in histopathologically equivocal cases, such as lesions on lips or scalp (2 cases), in which a distinction from lichen planus was not possible, neither clinically or histopathologically.

Conclusion

Direct immunofluorescence is a useful diagnostic technique in the diagnosis of cutaneous LE; however, it should be used in conjunction with hematoxylin and eosin-stained sections. It is likely to be negative in early cases, but is particularly helpful in lesions of mucous membranes and/or scalp.

References

1. Tan EM, Cohen AS, Fries JF *et al.* The 1982 revised criteria for the classification of systemic lupus erythematosus. *Arthritis Rheum* 1982; **25**: 1271-7.

2. Epstein JH, Tuffanelli DL, Dubios EL. Light sensitivity and LE. *Arch Dermatol* 1965; **91**: 483-6.
3. Isabel B, Carmen H, Antonio C *et al.* Histologic findings in cutaneous lupus erythematosus. *Arch Dermatol* 1994; **130**: 54-8.
4. Burnham TK, Neblett TR, Fine G. The application of the fluorescent antibody technique to the investigation of lupus erythematosus and various dermatoses. *J Invest Dermatol* 1963; **41**: 451-6.
5. Burnham TK, Fine G. The immunofluorescent "band" for lupus erythematosus. Morphological variations of the band of localized immunoglobulins at the dermoepidermal junction in lupus erythematosus. *Arch Dermatol* 1969; **99**: 413-20.
6. Cormane RH. "Bound" globulin in the skin of patients with chronic discoid lupus erythematosus and systemic lupus erythematosus. *Lancet* 1964; **1**: 534-5.
7. Lever FW, Schaumberg-Lever D. Connective tissue diseases. In: *Histopathology of the Skin*. Philadelphia: JB Lippincott; 1990. P. 494-514.
8. Al-Swaid AR, Venkataram MN, Bhushnurmath SR. Cutaneous lupus erythematosus: comparison of direct immunofluorescence findings with histopathology. *Int J Dermatol* 1995; **34**: 480-2.
9. Tuffanelli DL. Cutaneous immunopathology; recent observations. *J Invest Dermatol* 1975; **65**: 143-53.
10. Immunodermatology. *Dermatol Clin* 1990; **8**: 593-794.
11. Blaszczyk M, Dahl MV. Usefulness of direct immunofluorescence in patients with lupus erythematosus. *Arch Dermatol* 1983; **119**: 1010-7.
12. Nieboer C. The reliability of immunofluorescence and histopathology in the diagnosis of discoid lupus erythematosus and lichen planus. *Br J Dermatol* 1987; **116**: 189-98.
13. Weigand DA. Lupus band test: anatomic regional variations in discoid lupus erythematosus. *J Am Acad Dermatol* 1986; **14**: 426-8.
14. Beutner E, Jablonska S, Kumar V. Direct immunofluorescence in lupus erythematosus. In: Beutner E, Chorzelski TP, Beau SF, eds. *Immunopathology of Skin*. New York: Wiley Medical Publication; 1987. P. 499-523.