

## Case Report

# Subungual glomus tumor – a case report

Sajad Ahmad Salati, Ajaz Rather, Arshad Bashir Khan

Department of Surgery, Sheri Kashmir Institute of Medical Sciences (Medical College), Srinagar, Kashmir-India

**Abstract** Glomus tumor is a rare benign neoplasm that arises from the neuroarterial structure called a glomus body and accounts for 1 % to 2 % of soft tissue tumors in the hand. We present a case of a 36-year-old female who was treated for subungual glomus tumour of thumb.

**Key words**

Glomus tumor, benign, transungual approach.

### Introduction


Glomus tumor is a rare tumor arising from a neuromyoarterial glomus,<sup>1</sup> which is an arteriovenous anastomosis functioning without an intermediary capillary bed. Normal glomus bodies aid in the regulation of skin circulation and to be highly concentrated in the finger tips, particularly beneath the nail. Treatment of this lesion is complete surgical excision. We treated a 36 years old female patient who was suffering from obscure pain due to the subungual glomus tumor of her left thumb.

### Case report

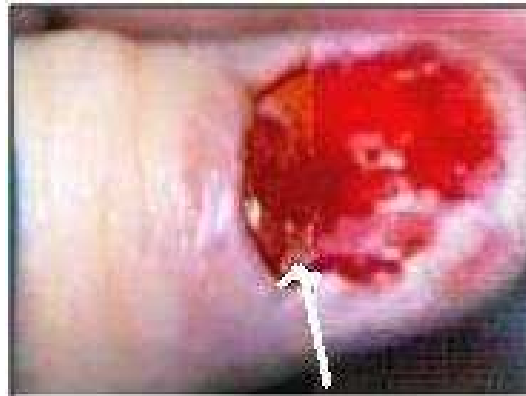A 36-year-old lady presented with two years history of pain in left thumb aggravated during winter months and by working with cold water. There was no history of trauma nor was there any other past medical or surgical history of significance. On examination, there was a bluish discoloration at the base of nail plate (**Figure 1**) and this spot was exquisitely tender. Hildreth's and Love's signs were positive. Plain films of the affected thumb did not reveal any abnormality. MRI of the affected thumb was planned but the patient could not afford the cost of this study. Patient was operated upon under local anesthesia

**Address for correspondence**

Dr. Sajad Ahmad Salati  
Lane 2, Bulbul Bagh, Barzullah,  
Srinagar, Kashmir.  
Email: docsajad@yahoo.co.in  
Mobile: 00919906531987



**Figure 1** Subungual glomus tumor of right thumb (black arrows shows bluish discoloration).



**Figure 2** Glomus tumor (white arrow) as seen after removal of nail-plate.

(digital block) with 1% xylocaine with proximal tourniquet control. Through transungual approach, 0.5cm x 0.5cm shiny, pinkish, encapsulated lesion was found arising from nail bed (**Figure 2**). This lesion was excised in toto. Histopathological analysis of the lesion confirmed the diagnosis of benign

glomus tumor. The patient had an uneventful postoperative period and was symptom free and satisfied at 6 months follow-up.

## **Discussion**

Glomus tumor is a rare and benign vascular tumor<sup>1</sup> and constitutes 1-2% of the soft-tissue tumors in the hand. In 1812, glomus tumor was described by Wood as a painful subcutaneous "tubercle".<sup>2</sup> Fifty percent of these occur under the fingernail, usually to people between the ages of 30 and 50 years, twice as often to women as men.<sup>1-3</sup> Multiple glomus tumors are present in 2.3% of cases.<sup>4</sup> The normal glomus unit is a neuromyoarterial apparatus that functions to regulate skin circulation and is found subungually, on the finger tip pulp, on the base of the foot and the rest of body in descending order. Glomus tumor arises from the arterial portion of the glomus body, or the Sucquet-Hoyer canal of this apparatus. The initiating event for glomus cell proliferation is unknown. Some authors have postulated that trauma induces solitary subungual glomus tumors, although this theory is not well studied. Other synonyms for glomus tumors include glomangioma, tumor of the neuromyoarterial glomus, angioneuromyoma, and Popoff tumor.<sup>5</sup>

Clinically, glomus tumors are characterized by a triad of sensitivity to cold, localized tenderness and severe and intermittent pain.<sup>6</sup> The pain can be excruciating and is described as a burning or bursting. The exact cause of the pain is unknown, but nerve fibers containing the pain neurotransmitter substance P have been identified in the tumor.<sup>7</sup>

Diagnosis of glomus tumors is primarily clinical. Several clinical tests are useful for diagnosing glomus tumors. Love<sup>8</sup> reported that localization of the tenderness to an area and the size of a pinhead were suggestive of glomus tumor. For a positive Love's pin test,

the patient should experience severe pain when the skin overlying the tumor is pressed with a ballpoint pen, end of a paperclip, pinhead or K- wire. The cold-sensitivity test is positive when immersing the hand in cold water for 60 seconds elicits severe pain in and around the lesion. In addition, there should be a history of cold weather aggravating the symptoms as was evident in our patient. Hildreth's test is another reliable clinical sign for the diagnosis of glomus tumors.<sup>9</sup> This test is performed by elevating the patients' arm to exsanguinate it. A tourniquet is inflated to 250 mm Hg and if test is positive than there is reduction in pain and tenderness. A test is also positive when releasing the cuff causes a sudden onset of pain and tenderness in the area of the tumor.

Plain films generally are not helpful in visualizing this tumor though in longstanding cases may reveal a concave contour deformity of the phalanx or a focal, well-defined cortical lucency.<sup>10</sup> CT Scan imaging does not add anything valuable for diagnosis and ultrasound in expert hands can identify these lesions as solid hypo echoic foci.<sup>11</sup> In addition, the localized and enlarged blood vessels encased by the tumor may be visualized on color Doppler. But high resolution magnetic resonance imaging (HR-MRI) has been found to be specific and sensitive tool for diagnosis of glomus tumors and can detect lesions as small as only 1mm.<sup>8</sup> Most glomus tumors show high signal intensity on T2-weighted spin-echo MR images and strong enhancement after injection of a gadolinium compound.<sup>12,13</sup>

Subungual glomus tumors are treated by surgical excision. The tumor may be approached by subungual or lateral approach and in either method, the nail plate is reflected and the tumor is exposed and excised along with capsule. The incidence of tumor recurrence after surgical excision ranges from

5% to 50% depending primarily on the surgical technique.<sup>14</sup>

## References

1. Theumann NH, Goettmann S, Le Viet D *et al.* Recurrent glomus tumors of fingertips: MR imaging evaluation. *Radiology* 2002; **223**: 143-51.
2. Wood W. On painful subcutaneous tubercle. *Edinb Med J* 1812; **8**: 283-91.
3. Van Ruyssevelt CE, Vranckx P. Subungual glomus tumor: Emphasis on MR angiography. *Am J Roentgenol* 2004; **182**: 263-4.
4. Heys SD, Brittenden J, Atkinson P, Eremin O. Glomus tumour: an analysis of 43 patients and review of the literature. *Br J Surg* 1992; **79**: 345-7.
5. Fornage BD. Glomus tumors in the fingers: diagnosis with US. *Radiology* 1988; **167**: 183-5.
6. Vandevender DK, Daley RA. Benign and malignant vascular tumors of the upper extremity. *Hand Clin* 1995; **11**: 161-79.
7. Kishimoto S, Nagatani H, Miyashita A, Kobayashi K. Immunohistochemical demonstration of substance P containing nerve fibers in glomus tumors. *Br J Dermatol* 1985; **113**: 213.
8. Love JG. Glomus tumors: diagnosis and treatment. *Proc Staff Meet Mayo Clin* 1944; **19**:113-6.
9. Giele H. Hildreth's test is a reliable clinical sign for the diagnosis of glomus tumor. *J Hand Surg Br* 2002; **27**: 157-8.
10. Murphey MD, Fairbairn KJ, Parman LM *et al.* From the archives of the AFIP. Musculoskeletal angiomatous lesions: radiologic-pathologic correlation. *Radiographics* 1995; **15**: 893-917.
11. Wortsman X, Jemec GB. Ultrasound imaging of nails. *Dermatol Clin* 2006; **24**: 32.
12. Drape JL, Idy-Peretti I, Goettmann S *et al.* Subungual glomus tumors: evaluation with MR imaging. *Radiology* 1995; **195**:507-15.
13. Hou SM, Shih TTF, Lin MC. Magnetic resonance imaging of an obscure glomus tumor in the finger tip. *J Hand Surg Br* 1993; **18**: 482-3.
14. Van Geertruyden J, Lorea P, Goldschmidt D *et al.* Glomus tumours of the hand: a retrospective study of 51 cases. *J Hand Surg Br* 1996; **21**: 257-60.

For timely delivery of JPAD, members of Pakistan Association of Dermatologists are requested to update their mailing address with editorial office.