

Case Report

Ichthyosis bullosa of Siemens sans history of blistering: an interesting case report

Sankha Koley, Atul Salodkar, Sumit Gupta, Arvind Bhanke*, Ashish Ujawane**, Shazia Bisati

Department of Dermatology, J.N.M.C. Wardha, Maharashtra, India.

*Department of Pathology, J.N.M.C. Sawangi, Wardha, Maharashtra, India

**Department of Medicine, J.N.M.C. Sawangi, Wardha, Maharashtra, India

Abstract Ichthyosis bullosa of Siemens (IBS) is a rare disease characterized by superficial blistering, mild epidermal hyperkeratosis over flexural areas and characteristic mauserang phenomenon (moulting). We report an interesting case of IBS in a mentally retarded hypothyroid patient who did not give any history of blistering. Histological examination of specimen from margin of an area exhibiting mauserang phenomenon revealed epidermolytic hyperkeratosis in granular and upper spinous layers. In situations where proper clinical history cannot be elicited, the histopathological findings have paramount importance.

Key words

Ichthyosis bullosa of Siemens, bullous

Introduction:

Ichthyosis bullosa of Siemens (IBS:MIM:146800) was first described by Siemens¹ in 1937 and since then this entity had fallen in oblivion. It was again resurrected by Traupe *at al.* when they described the second family in 1986.² It is a unique congenital autosomal dominant ichthyosis characterized by superficial blistering, mild epidermal hyperkeratosis over flexural areas and characteristic superficially denuded peeling areas - the so called "mauserang phenomenon" (moulting).¹

While it has number of similarities to bullous congenital ichthyosiform erythroderma (BCIE:MIM:113800), the clinical features are much milder and it is caused by mutation in

gene encoding keratin 2e (while BCIE is caused by mutation in keratin 1 and 10).³

Histopathological examination reveals more subtle type of epidermolysis in the granular and upper spinous layers, which is compatible with epithelial cytokeratin 2e being only expressed in these two layers. In CBIE the deeper suprabasal layers are also involved.

We report an interesting case report of IBS in a mentally retarded hypothyroid patient.

Case report

A 16-year-old mentally retarded male patient presented with dry skin and recurrent peeling of skin since birth. The dryness and peeling of the skin had increased in the recent past. He denied any history of blistering. The patient was suffering from hypothyroidism and was taking thyroxine tablets since childhood. He could not give proper history. He was orphaned in early

Address for correspondence

Dr. Sankha Koley
9 Mandeville Gardens, Flat 10C,
Calcutta-700019; West Bengal, India
Email: skoley@gmail.com

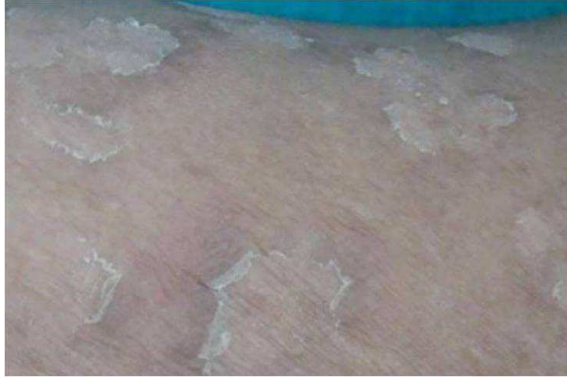

Figure 1 Typical mauserung phenomenon

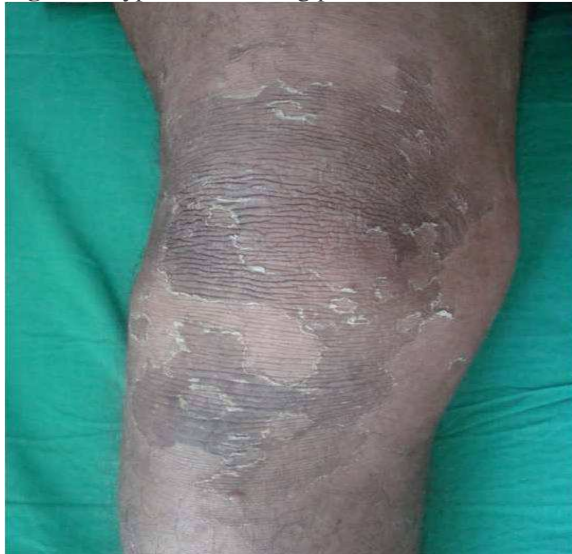

Figure 3 Peeling of skin and hyperkeratosis in rippled pattern on knee.

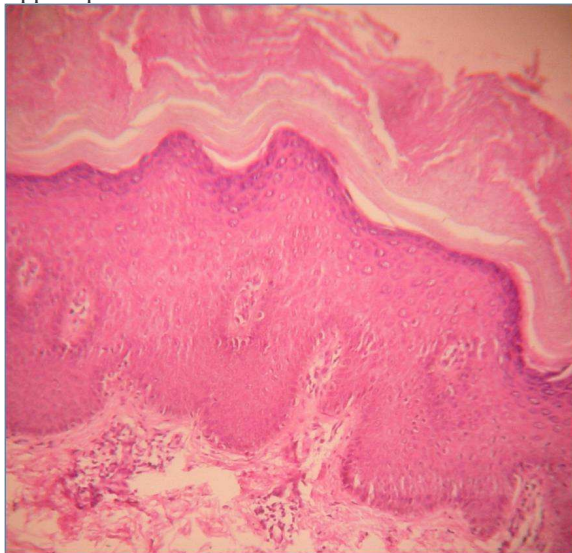


Figure 5 Epidermolytic hyperkeratosis involving stratum granulosum and upper layers of stratum spinosum (HEX40).

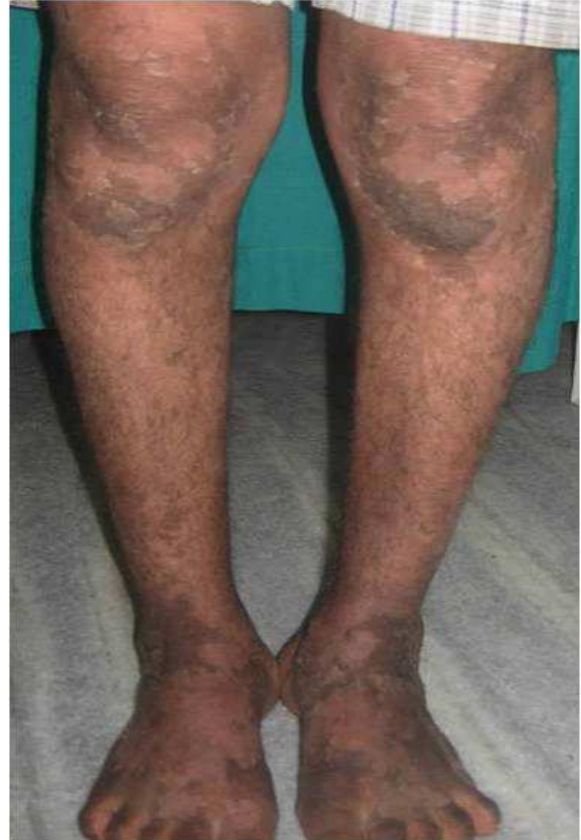

Figure 2 Peeling of skin with flexural dirty grey hyperkeratosis with typical rippled pattern on anterior aspect of leg and knees.

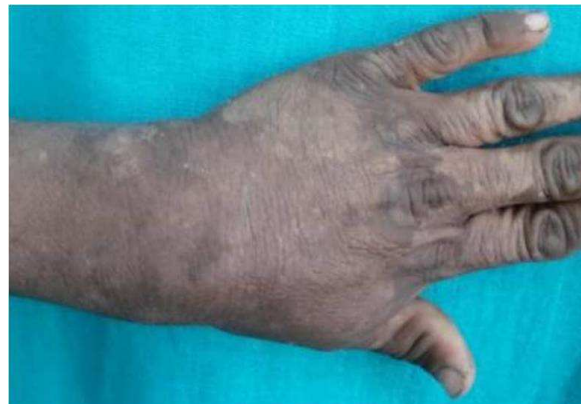

Figure 4 Peeling of skin from dorsum of hand.

childhood and no information could be obtained about his parents. He was accompanied by two social workers of his orphanage who were unaware about detailed history of his illness.

On examination, the patient revealed low intelligence, dull lethargic look and a slow monotonous speech. There were multiple circumscribed areas of peeling of the skin, similar to mauserang phenomenon (moulting) [Figure1] described by Siemens.¹

The mauserang phenomenon was restricted to different sites and involved knees, elbows, dorsum of hands, buttocks and parts of the trunk (Figures 2, 3 and 4). The flexural aspects of the legs showed dirty grey hyperkeratosis with typical rippled pattern. His palms, soles, hair, nails were normal. There was no involvement of mucosa.

Histological examination of specimen from margin of an area exhibiting mauserang phenomenon showed hyperkeratosis, acanthosis and epidermolytic hyperkeratosis involving stratum granulosum and upper layers of stratum spinosum (Figure5). Genetic studies were not done as these facility was not available in our set up.

A clinicopathological correlation was made and a provisional diagnosis of ichthyosis bullosa of Siemens was made. The patient was prescribed white soft paraffin; to be applied on the body liberally at least twice daily. However the patient was lost to follow up.

Discussion

IBS is predominantly inherited as autosomal dominant disease with occasional reports of sporadic mutation. The differentials are epidermolysis bullosa simplex, skin peeling syndrome and autosomal dominant types of ichthyosis-like ichthyosis vulgaris and CBIE. The clinical features that distinguish IBS from CBIE are the lack of erythroderma, typical

mauserang phenomenon, localization of epidermolytic changes to superficial epidermal layers and presence of intracorneal blistering.

The flaking and blistering generally improve with age. The hyperkeratosis may grow more severe, but it stays localized to flexural folds. Rajiv and Rakesh described a 14-year-old boy whose blistering improved with age but the problem of skin peeling increased with age.⁴ In her 35-year-old mother blistering decreased with age and eventually ceased. Our patient did not give any history or clinical evidence of blistering at the time of presentation. We assume that events of blistering were present after birth. But they decreased and ceased with age. However, due to low intelligence, he could not give proper history. As family history could not be properly elicited, we do not know that case was familial or sporadic. However, electron microscopic analysis for the definitive diagnosis of the patient could not be done as this facility was not available in our institute.

IBS is a rare condition (1 in 500,000)⁵ and it is less common than BCIE (1 in 250,000).⁶ According to Akiyama *et al.* till 2005 only 19 kindreds of IBS had been reported before. However, IBS might not be so rare. It is clinically difficult to distinguish severe IBS from mild BCIE. Many cases which were earlier diagnosed wrongly as BCIE, can now be diagnosed accurately as IBS by mutational analysis (mutation in gene encoding 2e).⁷ E493K is the most commonly reported mutation to date and might represent mutational hotspot of the disease.⁸

There is no cure for IBS but in the future gene therapy may offer a solution. Liberal and frequent application of emollient may control the disease in most cases. Low doses of systemic

retinoids (etretinate and acitretin) have been used successfully to control resistant cases.⁹ But retinoids may cause blistering themselves.¹⁰ Few have found daily use of tazarotene 0.05% gel for four weeks satisfactory⁴ while others have not found it to be useful.¹¹

Though erythroderma is classically absent in IBS, there is a report of erythroderma in an index patient of a large family involving eight members, spanning three generations.⁸ As family history could not be elicited, we do not know whether our case was familial or sporadic.

In situations where proper clinical history cannot be elicited, the histopathological findings are of paramount importance. Paucity of reports of IBS and the need to stress the importance of clinicopathological correlation have prompted us to report the case here.

References

1. Siemens HW. Dichtung und Wahrheit über die "Ichthyosis bullosa," mit bemerkungen zur systematik der rpidermolysen. *Arch Dermatol Syph* 1937; **175**: 590-608. [Quoted by: Traupe H, Kolde G, Hamm H, Happle R. Ichthyosis bullosa of Siemens: a unique type of epidermolytic hyperkeratosis. *J Am Acad Dermatol* 1986; **14**: 1000-5.]
2. Traupe H, Kolde G, Hamm H, Happle R. Ichthyosis bullosa of Siemens: a unique type of epidermolytic hyperkeratosis. *J Am Acad Dermatol* 1986; **14**: 1000-5.
3. Kremer H, Zeeuwen P, McLean WH *et al*. Ichthyosis bullosa of Siemens is caused by mutations in the keratin 2e gene. *J Invest Dermatol* 1994; **103**: 286-9.
4. Rajiv S, Rakesh SV. Ichthyosis bullosa of Siemens: response to topical tazarotene. *Indian J Dermatol Venereol Leprol* 2006; **72**: 43-6.
5. Caputo R, Gianluca T, eds. *Atlas of Genodermatoses*. New York: Taylor & Francis; 2005.
6. Smith JB, Smith SB. Epidermolytic hyperkeratosis (bullous congenital ichthyosiform erythroderma). Updated: Jan 24, 2007.[cited on 20April 2009] Available from: <http://emedicine.medscape.com/article/1112403-overview>
7. Akiyama M, Tsuji-Abe Y, Yanagihara M *et al*. Ichthyosis bullosa of Siemens: its correct diagnosis facilitated by molecular genetic testing. *Br J Dermatol* 2005; **152**: 1353-6.
8. Basarab T, Smith FJ, Jolliffe VM *et al*. Ichthyosis bullosa of Siemens: report of a family with evidence of a keratin 2e mutation and a review of the literature. *Br J Dermatol* 1999; **140**: 689-95.
9. Vahlquist A, Duvic M, eds. *Retinoids and Carotenoids in Dermatology*. New York: CRC Press; 2007.
10. Hofmann B, Stege H, Ruzicka T, Lehmann P. Effect of topical tazarotene in the treatment of congenital ichthyoses. *Br J Dermatol* 1999; **141**: 642-6.