

Case Report

Necrobiotic xanthogranuloma – a case report

Muhammad Munir Rashid, Tamanna Chowdhury*, Abida Sultana, Rokeya Begum, Shiropa Islam, Iftexhar Ahmed

Department of Dermatology and Venereology, Bangabandhu Sheikh Mujib Medical University, Dhaka Bangladesh

* Department of Dermatology and Venereology, Bangabandhu Sheikh Mujib Medical University, Dhaka Bangladesh

Abstract We report here a 70-year-old lady with multiple large soft yellowish plaques around her eyes for last 10 years. Histopathological evaluation revealed a dense histiocytic infiltrate with hyaline necrobiosis involving the dermis with extension to the subcutis. Multiple large multinucleated giant cells and scattered lymphocytes were seen. Serum protein electrophoresis revealed nonspecific findings. Based on the clinical picture, and histopathology results, a diagnosis of necrobiotic xanthogranuloma was made.

Key words

Introduction

Necrobiotic xanthogranuloma (NXG) is a rare chronic progressive disease first described by Kossard and Winkelmann in 1980.¹ It is a multisystem disease with prominent skin findings that affect older adults. The characteristic skin lesions are periorbital yellow plaques and nodules which occur in 80% of cases.² These lesions resemble xanthelasma, except that they are deep, firm, indurated and may extend into the orbit. Lesions tend to enlarge and later undergo central ulceration followed by atrophy. NXG is a slowly progressive histiocytic disease that is associated with paraproteinemia in most cases; however, its pathogenesis remains unclear.³ Paraproteinemia is closely associated with NXG, with

approximately 80 percent of patients demonstrating a monoclonal gammopathy on serum protein electrophoresis; furthermore, 10 percent of these patients develop multiple myeloma.⁴ NXG may involve other extracutaneous sites, including the heart, lungs, kidneys, liver, spleen, intestines, skeletal muscle, and central nervous system⁵ and may be associated with arthropathy, hypertension, neuropathy neoplastic syndrome, primary biliary cirrhosis and Grave's disease. The histopathologic picture of NXG is characteristic and consists of granulomatous infiltrate involving the whole dermis and subcutis composed of a mixture of lymphocytes, epithelioid cells, foam cells and Touton giant cells.⁶

Case report

A 70-year-old lady reported to the outpatient department of Dermatology and Venereology of Bangabandhu Sheikh Mujib Medical University on 10th April, 2009 with complaints of gradually increasing yellowish papules and plaques around

Address for correspondence

Dr. Muhammad Munir Rashid.

Associate Professor.

Department of Dermatology,
Bangabandhu Sheikh Mujib Medical
University,

Room -309, Block -C

Shahbag, Dhaka, Bangladesh

88-01817048733 (mobile)

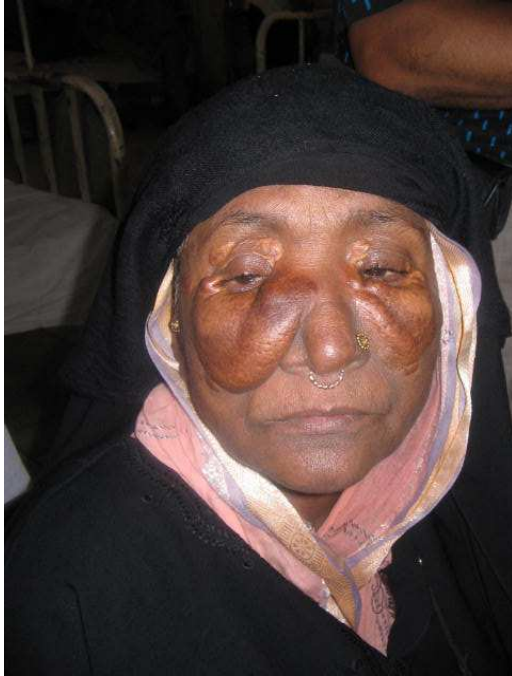

Figure 1 Photograph showing plaques over the face of the patient

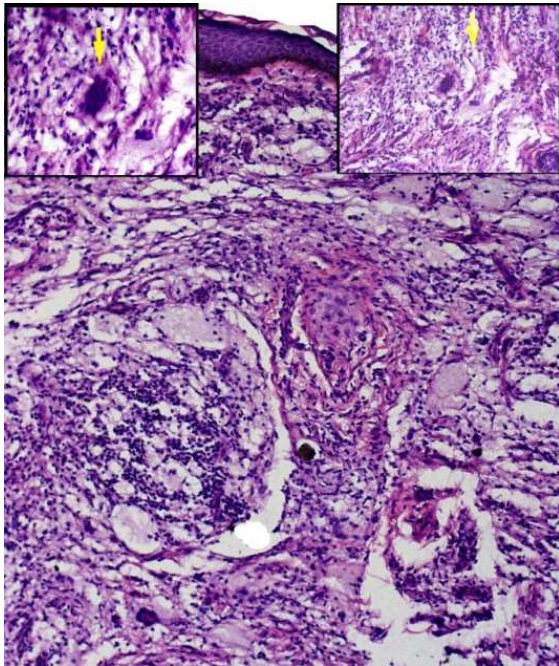


Figure 2 Histopathology of NBX showing foamy histiocytes (at inset right) and Touton giant cell (at inset left).

the eyes (**Figure 1**) for last 7 years. Lesions were mildly pruritic at early stage but became asymptomatic later on. For the last two years she had been experiencing recurrent conjunctivitis

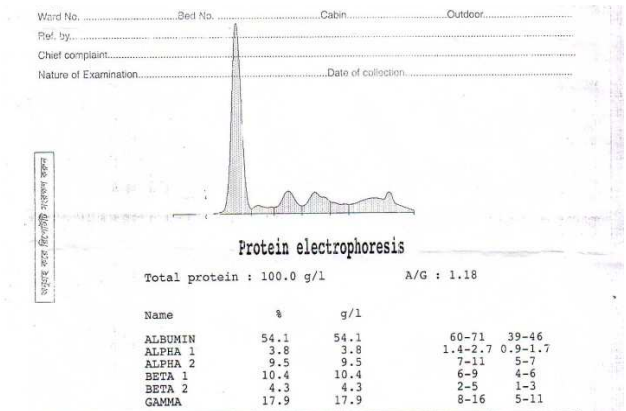


Figure 3 Showing serum protein electrophoresis result of the patient.

and blurring of vision. On examination by the ophthalmologists no abnormality was found. She was diabetic and hypertensive. She had 7 children, all healthy.

Histopathology from lesional skin revealed a diffuse, predominantly granulomatous infiltrate of foamy and multinucleated histiocytes, many of which were of the Touton type (**Figure 2**). Her routine blood count revealed a normocytic hypochromic anemia and high erythrocyte sedimentation rate and serum protein electrophoresis shown a non specific finding (**Figure 3**).

Discussion

Necrobiotic xanthogranuloma is a systemic disease associated in most cases with monoclonal paraproteinemia but in our case there was a polyclonal picture. Although the causative role of the paraproteinemia is supposed, the pathogenesis of this disease remains unknown. Theories regarding pathogenesis include deposition of immunoglobulins and lipid complexes with a foreign body giant-cell reaction and monocyte activation with intracellular lipid accumulation.⁷ The association between NXG

and paraproteinemia is well documented. However, the skin lesions in NXG represent reactive inflammation and are not associated with the presence of monoclonal plasma cells or multiple myeloma.⁴ Hepatosplenomegaly, an increased erythrocyte sedimentation rate, leucopenia, hypocomplementemia, and cryoglobulinemia are other common findings.⁸ Treatment consists of systemic corticosteroids, low dose chlorambucil, plasmapheresis or local radiation therapy. Interferon (IFN)- α 2b in combination with systemic corticosteroid and pulse cyclophosphamide with dexamethasone produced dramatic improvement.⁹ The prognosis in given cases is difficult to predict and depends on extra cutaneous involvement and the presence of visceral tumours such as multiple myeloma.⁶

Reference

1. Kossard S, Winkelmann RK. Necrobiotic xanthogranuloma. *Australas J Dermatol* 1980; **21**: 85-8.
2. James WD, Berger TG, Elston DM, eds. *Andrew's Disease of the Skin*. Philadelphia: Saunders Elsevier; 2006, p 707-8.
3. Wee SA, Shupack JL. Necrobiotic xanthogranuloma. *Dermatology Online Journal* 2005; **11**: 24.
4. Mehregan DA, Winkelmann RK. Necrobiotic xanthogranuloma. *Arch Dermatol* 1992; **128**: 94.
5. Winkelmann RK, Litzow MR, Umbert IJ, Lie JT. Giant cell granulomatous pulmonary and myocardial lesions in necrobiotic xanthogranuloma with paraproteinaemia. *Mayo Clin Proc* 1997; **72**: 1028-33.
6. Necrobiotic xanthogranuloma. Wolff K, Goldsmith LA, Katz SI *et al.* (eds). *Dermatology in General Medicine, 7th Edn*. Philadelphia: McGraw-Hill; 2008. P. 1432-3.
7. Matsuura F, Yamashita S, Hirano K *et al.* Activation of monocytes in vivo causes intracellular accumulation of lipoprotein-derived lipids and marked hypercholesterolemia: a possible pathogenesis of necrobiotic xanthogranuloma. *Atherosclerosis* 1999; **142**: 355-65
8. Finan MC, Winkelmann RK. Necrobiotic xanthogranuloma with paraproteinaemia: a review of 22 cases. *Medicine* 1986; **65**: 376-88.
9. Venencie PY, Le Bras P, Toan ND *et al.* Recombinant interferon alpha-2b treatment of necrobiotic xanthogranuloma with paraproteinaemia. *J Am Acad Dermatol* 1995; **32**: 666-7.