

Case Report

Malignant fibrous histiocytoma: An uncommon soft tissue sarcoma

Muhammad Amjad, Arfan ul Bari*

Consultant Dermatologist, Rahman Medical Institute, Hayat Abad, Peshawar

*Dermatology Department, Combined Military Hospital, Peshawar

Abstract Malignant fibrous histiocytoma is a type of histiocytoma that is the most common soft tissue sarcoma of late adult life. These tumors rarely involve the head and neck region. In this report we describe an elderly patient with rapidly evolving soft tissue growth starting at bridge of the nose along with swelling right side of neck. Histopathology and imaging studies revealed diagnosis of malignant fibrous histiocytoma. Patient was evaluated thoroughly and referred to oncologist

Key words

Histiocytoma, malignant fibrous histiocytoma, soft tissue sarcoma.

Introduction

Malignant fibrous histiocytoma (MFH), described by O'Brien and Stout in 1964, is a soft-tissue sarcoma most commonly occurring between age 50-70.¹ In rare cases MFH does occur in children, but it is usually in a less aggressive form. It is seen more often in Caucasian males than those of African or Asian descent. MFH occurs most commonly in the extremities (70-75%) with lower extremities accounting for 59% of cases), followed by the retroperitoneum. Tumors typically arise in deep fascia or skeletal muscle. MFH has been reported to occur in the lung, kidney, bladder, scrotum, vas deferens, heart, aorta, stomach, small intestine, orbit, CNS, paraspinal area, dura mater, facial sinuses, nasal cavity, oral cavity, nasopharynx, and soft tissues of the neck.^{2,3} MFH may also occur secondary to radiation exposure and shrapnel injury and may be seen

adjacent to metallic fixation devices, including total joint prostheses.⁴ The most common clinical presentation is an enlarging painless intramuscular soft-tissue mass in the thigh, typically 5-10 cm in diameter. Rare signs and symptoms include episodic hypoglycemia and rapid tumor enlargement during pregnancy. MFH has also been associated with hematopoietic diseases such as non-Hodgkin lymphoma, Hodgkin lymphoma, multiple myeloma, and malignant histiocytosis. Retroperitoneal MFH usually presents with constitutional symptoms, including fever, malaise, and weight loss. Development of metastasis depends on the tumor's subtype and it occurs most frequently in the lungs (90%), bone (8%) and liver (1%). As with other soft-tissue tumors, MFH can be detected by magnetic resonance imaging (MRI), but a biopsy is required for definitive diagnosis. MRI is the imaging method of choice because of its ability to provide superior contrast between tumor and muscle, excellent definition of surrounding anatomy, and ease of imaging in multiple planes. Treatment consists of surgical excision (the extent of which ranges from tumor excision to limb amputation depending on the tumor) and in

Address for correspondence

Lt Col. Dr. Arfan ul Bari,
Consultant Dermatologist,
Combined Military Hospital,
Peshawar, Pakistan
E-mail: albariul@yahoo.com,
albariul@gmail.com

some cases chemotherapy and radiation. Early and complete surgical removal using wide or radical resection is indicated because of the aggressive nature of the tumor.^{2,3,5} Although local control of the primary tumor is critical to successful treatment of both high- and low-grade lesions, the high rate of distant metastases in high-grade tumors supports the role of combined modality therapy. Adjuvant radiotherapy is generally recommended for high-grade sarcomas, large tumors, close or positive surgical margins, and certain histologic variants. Systemic chemotherapy is recommended for those tumors with a significant risk of distant metastases. The advent of more advanced reconstructive techniques, including free tissue transfer, has made more aggressive surgical resection of these tumors possible.⁶ 5-year survival ranges from 35-60%. The clinical stage of the tumor, which is defined by tumor grade, size, and presence of distant metastases, is the most important prognostic factor. Other factors include histologic subtype, method of surgical treatment, anatomic site and depth of the primary tumor may also be of prognostic importance.⁷

Case report

A 70-year-old male presented with 3-months history of rapidly increasing swelling over the bridge of nose. A month later he noticed enlarging firm swelling over right side of his neck. There was no history of fever, headache, shortness of breath, nasal or postnasal discharge or dysphagia. On examination, the patient was a healthy looking individual with normal vital signs. On local examination the swelling over nose was soft to firm, nonfluctuant, nontender and had overlying telangiectasias. The neck swelling was vertically oblong 5cm x 2.5cm, firm, irregular, non tender and not adherent to the overlying normal looking skin (**Figure 1a**

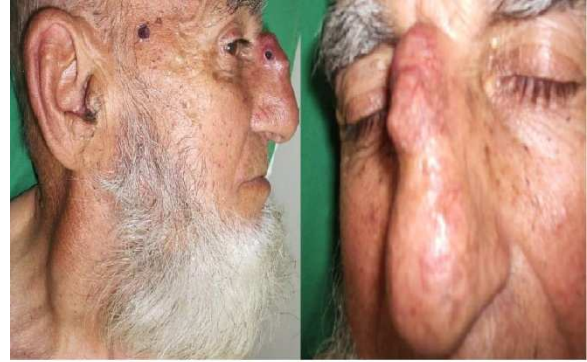

Figure 1 (a) A soft tissue swelling over nose with overlying telangiectasias. (b) A vertically oblong soft tissue swelling on side of the neck with overlying normal looking skin

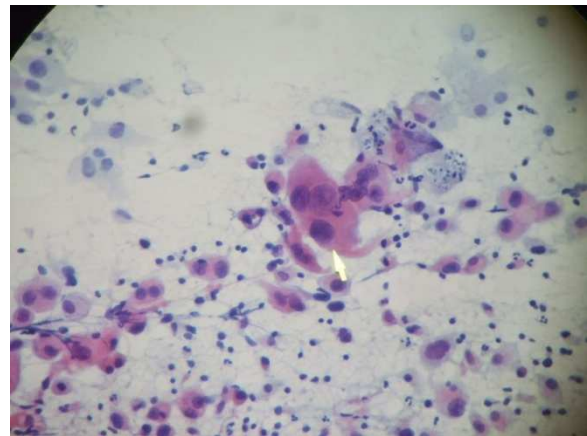


Figure 2 Fine needle aspiration smear from the neck swelling, showing cells with pleomorphic and spindle cell type morphology along with giant cells in rich inflammatory infiltrate.

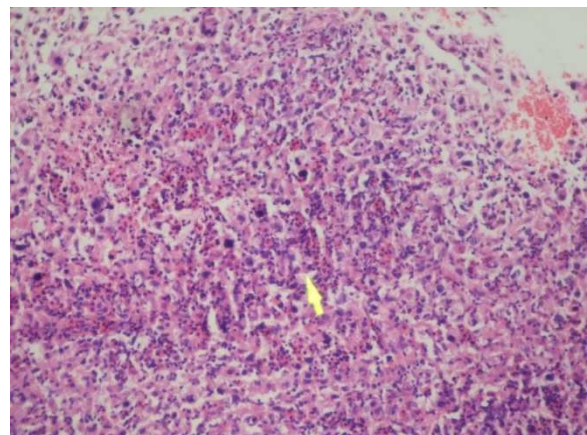


Figure 3 Histopathology of nasal lesion showing malignant cell infiltration with epithelioid/spindle cell type morphology, having abundant eosinophilic cytoplasm with hyperchromatic, pleomorphic nuclei. Scattered multinucleate giant cells and mitoses are also seen.

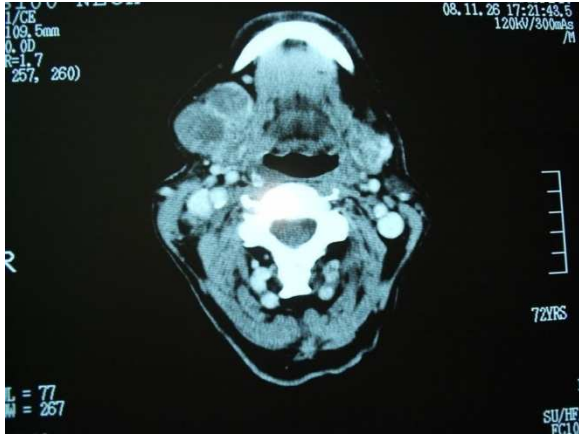


Figure 4 An enlarged lymph node compressing and anteriorly displacing right internal jugular vein.

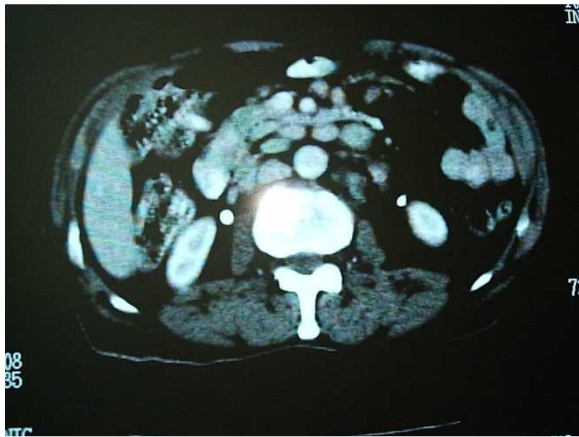

Figure 5 Hypodense lesions are seen in the liver. Para aortic lymph nodes are also enlarged.

and **1b**). There was a firm, mobile submandibular lymph node on right side as well. No other lymph nodes were palpable. Examination of chest revealed scattered crepitations bilaterally on auscultation. There was no visceromegaly. Fine needle aspiration smear from the neck swelling showed cells with pleomorphic and spindle cell type morphology in rich inflammatory infiltrate. (**Figure 2**). Histopathology of nasal lesion (**Figure 3**) showed highly malignant cell infiltration with epithelioid/spindle cell type morphology, having abundant eosinophilic cytoplasm with hyperchromatic, pleomorphic nuclei. Scattered multinucleate giant cells, abundant mitoses and necrosis were seen. Computerized tomographic

scan of neck and chest revealed enlarged right sided necrotic lymph nodes in right submandibular area and groups along sternocleidomastoid muscle. These extended beyond the lymph node capsule to adjacent fatty tissue. An enlarged lymph node was seen compressing and anteriorly displacing right internal jugular vein (**Figure 4**). Laryngeal cartilages were intact and thyroid gland showed normal parenchyma. Computerized tomographic scan of chest revealed matted calcified mediastinal lymphadenopathy with bilateral subsegmental consolidation. There were hypodense lesions in the liver. Para-aortic lymph nodes were enlarged (**Figure 5**). After determining the nature and extent of the disease, the patient was referred to the oncologist for further management.

Discussion

MFH accounts for 20-24% of soft-tissue sarcomas, making it the most common soft-tissue sarcoma occurring in late adult life. The combination of infrequent occurrence, varied pathologic features, uncertain histogenesis, numerous subtypes and the many potential sites of presentation makes these tumors a challenge for the diagnostician, surgeon and oncologist. Both histiocytic and primitive mesenchymal cell theories of origin have been postulated.^{8,9} In general, the tumor contains both fibroblast like and histiocyte like cells in varying proportions, with spindled and rounded cells exhibiting a storiform arrangement. Five histologic subtypes have been described: (1) storiform/pleomorphic, (2) myxoid, (3) giant cell, (4) inflammatory, and (5) angiomatoid.¹⁰⁻¹¹ Pleomorphic is the most commonly seen histologic variant of tumour and our case also belonged to this subtype. Primary cutaneous malignant fibrous histiocytoma is a rare entity and tends to occur more in females than males. Age of diagnosis is mostly between

second and fourth decades. The commonest site of origin among the cutaneous group is the extremities. It has been reported on the trunk but occurrence in the head and neck is rare. Tumors arising in sinonasal tracts are highly aggressive and are known to cause significant soft tissue invasion and bone destruction. Age of onset and site of origin of tumour in our patient was unusual as it had rarely been described in head and neck region and that too in elderly male. The sinonasal tracts which are the commonest sites of origin amongst the tumours of head and neck origin were thoroughly screened by otolaryngologist, but the tumour seemed to be originating from the skin. After thorough evaluation, the patient was sent to ENT surgeon for primary surgery and further follow up.

References:

1. O'Brien JE, Stout A P. Malignant fibrous xanthomas. *Cancer* 1964; **17**: 1445-55.
2. Gibbs JF, Huang PP, Lee RJ *et al*. Malignant fibrous histiocytoma: an institutional review. *Cancer Invest* 2001; **19**: 23-7.
3. Weiss SW, Enzinger FM. Malignant fibrous histiocytoma: an analysis of 200 cases. *Cancer* 1978; **41**: 2250-66.
4. Makimoto Y, Yamamoto S, Takano H *et al*. Imaging findings of radiation-induced sarcoma of the head and neck. *Br J Radiol* 2007; **80**: 790-7.
5. Kearney MM, Soule EH, Ivins JC. Malignant fibrous histiocytoma: a retrospective study of 167 cases. *Cancer* 1980; **45**: 167-78.
6. Sturgis EM, Potter BO. Sarcomas of the head and neck region. *Curr Opin Oncol* 2003; **15**: 239-52.
7. Pezzi CM, Rawlings MS Jr, Esgro JJ *et al*. Prognostic factors in 227 patients with malignant fibrous histiocytoma. *Cancer* 1992; **69**: 2098-103.
8. Ros PR, Viamonte M Jr, Rywlin AM. Malignant fibrous histiocytoma: mesenchymal tumor of ubiquitous origin. *Am J Roentgenol* 1984; **142**: 753-9.
9. Scapolan M, Perin T, Wassermann B *et al*. "Expression profiles in malignant fibrous histiocytomas: Clues for differentiating 'spindle cell' and 'pleomorphic' subtypes". *Eur J Cancer* 2007; **44**: 298-309.
10. Thway K. Angiomatoid fibrous histiocytoma: a review with recent genetic findings. *Arch Pathol Lab Med* 2008; **132**: 273-7.
11. Nascimento AF, Raut CP. Diagnosis and management of pleomorphic sarcomas (so-called "MFH") in adults. *J Surg Oncol* 2008; **97**: 330-9.

Manuscripts can be directly emailed to drijazhussain@gmail.com