

Short Communication

Co-occurrence of Isotopic and Isomorphic phenomenon in the same individual

Sir, a 35-year-old male presented with depigmented lesions suggestive of vitiligo on the lips, posterior aspect of hairline, trunk and lower extremities of 15-year duration. He also complained of itching on the neck at posterior aspect of hairline with loss of hair over the depigmented patch (**Figure 1**) since 5 months. Interestingly he also had depigmented lesions on an appendectomy scar over his abdomen (**Figure 2**) which had developed at the same time as the patchy loss of hair suggestive of isomorphic phenomenon.

Discussion

The isomorphic response, first defined by Koebner, indicates the appearance of typical skin lesions of an existing dermatosis at sites of injuries.¹ The term isotopic response refers to the occurrence of a new skin disorder at the site of another, unrelated, and already healed skin disease.¹ It was first defined by Wolf *et al.* in 1985 and hence is also known as Wolf's isotopic response.^{2,3}

The isomorphic response describes the appearance of a skin lesion which is morphologically similar to an existing skin disease at the site of an injury of any kind. Thus the term "isomorphic" means "the same morphology" (as the existing disease).⁴ In our case, patient had depigmented lesions on the appendectomy scar which suggested an isomorphic response.

The term "isotopic response" describes the

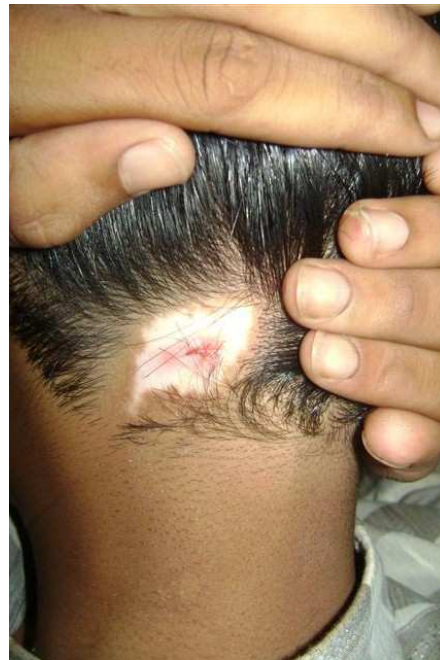

Figure 1 A vitiliginous patch with alopecia.

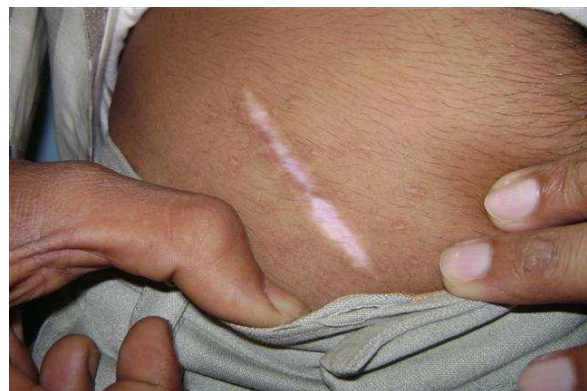

Figure 2 Depigmentation over appendectomy scar.

occurrence of a new, unrelated disease that appears at the same location as a previous disease; hence "isotopic" means "at the same place".⁴ Our patient developed alopecia areata over the vitiliginous patch on the neck at the posterior aspect of hairline suggesting an isotopic response. Previous case reports have described isotopic response in context of herpes simplex and herpes zoster. The second disease which have been reported are granuloma annulare, comedones, xanthoma, genital warts,

multiple epidermoid cysts, lichen planus, leukemia cutis, acne, squamous cell carcinoma or basal cell carcinoma.⁴⁻⁷

The cause of isotopic response is unknown however several authors have proposed viral, immunologic, neural, vascular and locus minoris resistentiae (a site of lessened resistance) to be the possible causes.⁵ A neural mechanism may be involved in the pathogenesis of both alopecia areata and vitiligo in which neurochemical mediators at the nerve endings have been implicated in the destruction of melanocytes, thus supporting the concept that neuropeptides may play a role in the pathogenesis of both alopecia areata and vitiligo.

In our case alopecia areata was present over the vitiliginous patch on the scalp along with vitiligo lesions over the surgical scars. Whether this could be a co-occurrence of alopecia areata over vitiligo or a type of isotopic response occurring simultaneously with isomorphic response in the same individual, we do not know. Our patient was treated with pimecrolimus 1% ointment twice daily and is under follow-up.

References

1. Wolf R, Brenner S, Ruocco V, Filioli FG. Isotopic response. *Int J Dermatol* 1995; **34**: 341-8.
2. Sharma RC, Sharma NL, Mahajan V, Sharma AK. Wolf's isotopic response: Herpes simplex appearing on scrofuloderma scar. *Int J Dermatol* 2003; **42**: 664-6.
3. Boyd AS, Neldner KH. The isomorphic response of Koebner. *Int J Dermatol* 1990; **29**: 401-10.
4. Thappa DM. Isotopic response versus isomorphic response. *Indian J Dermatol Venereol Leprol* 2004; **70**: 376.
5. Thappa DM. The isomorphic phenomenon of Koebner. *Indian J Dermatol Venereol Leprol* 2004; **70**: 187-9.
6. Feroze K, Siby G, Jayasree MG, Chirag P. Isomorphic and isotopic phenomenon occurring simultaneously in a case of granuloma annulare *Indian J Dermatol Venereol Leprol* 2009; **75**: 307-9
7. Turel A, Ozturkcan S, Sahin MT, Turkdogan P. Wolf's isotopic response: A case of zosteriform lichen planus. *J Dermatol* 2002; **29**: 339-42

Vandana Mehta, Bipin Bhattachan, C. Balachandran

Department of Skin & STD, Kasturba Medical College, Manipal, Karnataka, India .

Address for correspondence

Dr. Vandana Mehta
Department of Skin & STD
Kasturba Medical College
Manipal 576104, Karnataka, India
Email-vandanamht@yahoo.com

Trichoadenoma of Nikolowski

Sir, trichoadenoma is a rare benign, slowly growing, cutaneous tumor of the hair follicle first described by Nikolowsky in 1958. The tumor is less mature than a trichofolliculoma and is more differentiated than a trichoepithelioma with a differentiation towards the infundibular portion of the pilosebaceous canal.¹ We report a case of trichoadenoma on the nose which was clinically diagnosed as solitary trichoepithelioma.

A 48-year-old male presented with an asymptomatic solitary, skin-coloured nodule on the nose of 6 months duration. (**Figure 1**) There was no history of trauma prior to onset of the lesion. Clinically a diagnosis of solitary trichoepithelioma was entertained and the lesion was excised and sent for histopathology, which revealed keratinous horn cysts in the dermis without hair shaft formation surrounded by eosinophilic epithelial cells suggestive of a trichoadenoma. (**Figures 2 and 3**).

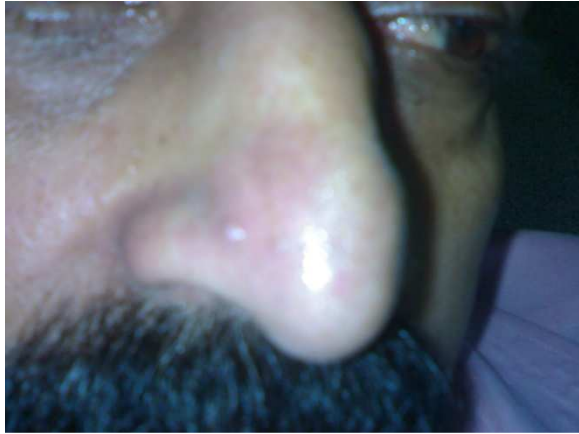

Figure 1 A skin-coloured nodule on nose.

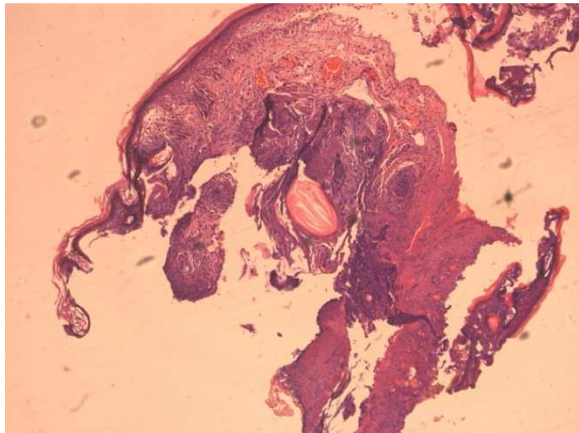


Figure 2 Keratinous horn cysts in the dermis without hair shaft formation surrounded by eosinophilic epithelial cells (4X).

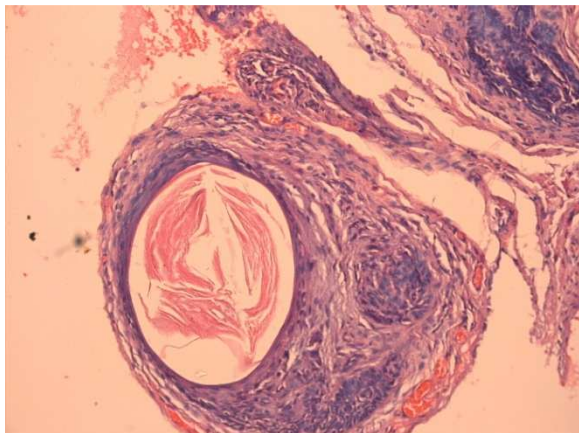


Figure 3 Histopathological picture on magnification (10X).

Discussion

Clinically, trichoadenoma occurs as a solitary elevated nodule most commonly on the face in 58% and to a less extent on the buttocks in 25%. Very occasionally the neck, upper arms, thighs, shoulder and shaft of penis may also be affected.^{2,3} Though it is usually seen in adults, childhood and congenital onset of the same has also been described in literature.⁴ Histologically, trichoadenoma characteristically shows numerous horn cysts throughout the dermis surrounded by eosinophilic epithelial cells, as was seen in our case. Solid epithelial islands of eosinophilic epithelial cells without central keratinization can also be seen.

In terms of morphologic differentiation, trichoadenoma is considered as an intermediate neoplasm between trichofolliculoma and trichoepithelioma, differentiating towards the infundibular portion of the pilosebaceous unit. Histologically, trichoepithelioma is characterized by presence of islands of basaloid cells with peripheral palisading and small horn cysts filled with keratin are usually present within the basaloid epithelial nests surrounded by dense fibroblastic stroma. At the other end of the spectrum, trichofolliculoma is a benign hamartoma that typically affects the face and represents abortive differentiation of cutaneous pluripotent stem cells towards hair follicles. Trichofolliculoma, histologically, comprises of a unilocular or multilocular keratin filled cystic cavity with hair shaft fragments, lined by infundibular squamous epithelium with prominent granular layer.⁵

In our case the clinical diagnosis was trichoepithelioma; however, histology showed features of a trichoadenoma. Hence to conclude, trichoadenoma is a rare neoplasm with fewer than 40 reported cases in English language literature. Even today this entity still remains as enigmatic as it was 49 years ago when it was

first discovered by Nikolowski, in terms of its morphological differentiation. In our case the lesion was excised by radiofrequency ablation and there has been no recurrence so far.

References

1. Reibold R, Undeutsch W, Fleiner J. Trichoadenoma of Nikolowski – review of four decades and seven new cases. *Hautarzt* 1998; **49**: 925-8.
2. Yu HJ, Yang HY, Kim YS. A case of trichoadenoma. *Korean J Dermatol* 1998; **36**: 372-5.
3. Lee WS, Oh ST, Lee JY, Cho BK. Congenital trichoadenoma with an unusual clinical manifestation. *J Am Acad Dermatol* 2005; **57**: 905-6.
4. Yamaguchi J, Takino C. A case of trichoadenoma arising in the buttock. *J Dermatol* 1992; **19**: 503-6.

5. Brenn T, McKee PH. Tumors of the hair follicle. In: McKee PH, Calonje E, Granter SR, editors. *Pathology of the Skin with Clinical Correlations*, 3rd edn. Philadelphia: Elsevier-Mosby; 2005. p. 1519-63.

Vandana Mehta, C. Balachandran

Department of Skin and STD, Kasturba Hospital, Manipal, Karnataka, India 576104

Address for Correspondence:

Dr. Vandana Mehta
Associate Professor
Department of Skin and STD,
KMC, Manipal, India
Email- vandanamht@yahoo.com

Erratum

In the original article 'Role of *Candida* antigen in treatment of viral warts: a placebo-controlled study' published in the July-September 2009 issue of the *Journal of Pakistan Association of Dermatologists*, page 146-150, the name of one of the authors '**Uzma Ali**' was missed. The correct reference should be read as "**Khawar Khurshid, Uzma Ali, Sabrina Suhail Pal**. Role of *Candida* antigen in treatment of viral warts: a placebo-controlled study. *J Pak Assoc Dermatol* 2009; **19 (3)**: 146-150."

In the case report 'Necrobiotic xanthogranuloma – a case report' authored by **Muhammad Munir Rashid, Tamanna Chowdhury, Abida Sultana, Rokeya Begum, Shiropa Islam, Iftekhar Ahmed** published in the July-September 2009 issue of the *Journal of Pakistan Association of Dermatologists*, page 175-177, the affiliated department of one of the authors was misprinted as Dr. Tamanna Chowdhury, Associate Professor of Dermatology, Bangabandhu Sheikh Mujib Medical University. The correct reference should be read as "Dr. Tamanna Chowdhury, Associate Professor of Pathology, Bangabandhu Sheikh Mujib Medical University, Dhaka"

