

Case Report

Alkaptonuria- a rare metabolic disorder

Khalid Mahmood Ranjha, Sohail Aslam, Tariq Mahmood

Department of Dermatology, Combined Military Hospital, Quetta, Pakistan.

Abstract A 26-year-old male presented with bluish discoloration of both pinnae and history of arthritis for the last few months. Examination showed bluish pigmentation of both pinnae, rest of the examination was unremarkable. Urine examination for the diagnosis of alkaptonuria was positive; however no radiological changes were seen at this stage of the disease. No other systemic abnormality or complication detected.

Key words

Alkaptonuria, homogentisic acid, ochronosis, arthritis.

Introduction

Alkaptonuria is a rare metabolic disorder first described by Garrod in 1902, which results from a single gene defect. It is an autosomal recessive condition characterized by a constitutional deficiency of homogentisic oxidase (homogentisic 1, 2-dioxygenase activity), with a deposition of oxidized homogentisic acid pigment throughout the body, particularly in fibrous and cartilaginous tissues. This disorder is degenerative and is further characterized by dark urine (homogentisic academia), distinctive cutaneous pigmentation (ochronosis) and arthritis. Generally, it is considered a benign disorder with normal life expectancy. Here, we report a case of this rare metabolic disorder.

Case report

A 26-year-old male reported in skin out patient department with history of bluish discoloration of ears. He first noticed an

asymptomatic progressive blue discoloration about three years earlier. He also complained of low backache and pain in both knee joints for the last few months. It was mild to moderate in intensity. Darkening of urine on air exposure was noticed by the patient a few months back when he saw the darkening of the ground where he used to micturate; he did not remember the staining of clothes during childhood. He also gave history of blackish wax in the ears. His parents were first cousins. He had three siblings and there was no family history of alkaptonuria.

On examination of skin there was remarkable greyish blue discoloration of the pinnae of both ears. The pinnae were thickened and flexible. Black cerumen was seen in the ears. Examination of sclerae, tendons, buccal mucosae, larynx, axillae, genitalia and nails revealed no abnormality. Systemic examination was unremarkable. Urine examination by ferric chloride and ammonical silver nitrate test confirmed the diagnosis of alkaptonuria. Sophisticated urine test like gas chromatography-mass spectrometry (GCMS) was not available in our setup so we had to depend on simpler

Address for correspondence

Maj. Dr. Khalid Mahmood Ranjha,
Classified Dermatologist,
Combined Military Hospital, Quetta, Pakistan.
Ph # 081-9209-6154.
E-mail address: ranjha_khalid@yahoo.com

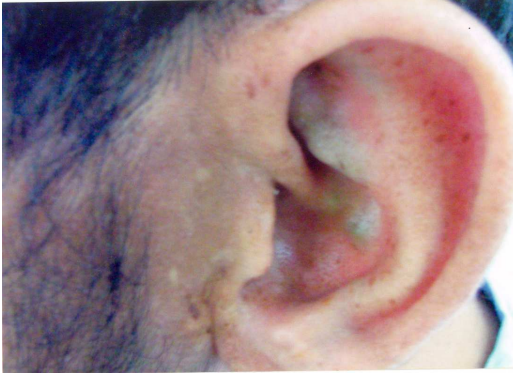

Figure 1 Greyish-blue pigmentation of left ear.



Figure 2 Urine examination by ferric chloride test.




Figure 3 Urine examination by ammonical silver nitrate test.

tests. The radiological examination of the lumbosacral spine and knee joints showed no degenerative changes or calcification of disks. All other investigations were within normal range.

On the basis of history, clinical examination and investigations a diagnosis of alkaptonuria was made. This patient was in early stage of the disease without any complication at the moment, he was advised to have a regular follow up.

Discussion

Alkaptonuria is a rare autosomal recessive disorder with an estimated incidence of 1 in every 250,000 to 1 million live births.¹ Alkaptonuria is caused by mutations in the HGA dioxygenase (HGD) gene that encodes HGD; an enzyme in the tyrosine degradation pathway. HGD converts HGA to maleylacetoacetic acid. Absence of this enzyme (HGD) results in massive accumulation of HGA and its oxidative products in connective tissue and urine. The oxidation products of HGA, including benzoquinoneacetic acid, are pigmented. Ochronosis refers to deposition of this pigment in the dermis of the skin that clinically appears blue-black in color.^{2,3}

The most prominent internal manifestation of alkaptonuria is arthritis that typically begins in the third decade of life.¹ Similar to ankylosing spondylitis, there is a tendency for large joint and spine involvement; however, arthritis associated with alkaptonuria tends to spare the sacroiliac region. Degeneration of disk spaces with subsequent calcification leads to kyphosis and loss of height. Decreased range of motion, effusions, and chronic joint pain are common. In addition to the spine, hips, knees, and shoulders are commonly involved. Of patients with alkaptonuria, 50% undergo at least one joint replacement operation by age 55 years.¹ Darkly

pigmented tendons, ligaments, and cartilage are often noted at the time of surgery as a result of HGA deposition within connective tissue.

Although connective tissue alterations resulting from alkaptonuria are well described, skin manifestations have not been emphasized. Ochronosis usually becomes evident in the sclera and cartilage of the ears after age 30 years.¹ The scleral pigmentation is prominent between the cornea and the outer and inner canthi at the insertion of the recti muscles. Slate gray to blue pigmentation of the ear begins in the concha and antihelix, and then progresses to the tragus. Occasionally a dusky discoloration of skin overlying tendons can be observed on the hands.² Brown discoloration of the axillae and groin is thought to be related to chronic exposure to pigmented sweat. Cerumen is also dark in color. Blue nails are less commonly seen. Hyperkeratotic linearly arranged blue papules along the lateral fingers and hands have been observed in several patients with alkaptonuria.

HGA in urine of patients with alkaptonuria oxidizes and darkens on exposure to air or with the addition of an alkalizing agent. This finding may be observed by the patient, because urine may remain normally colored at an acidic pH for several hours. In approximately 50% of cases, concern over dark-colored diapers prompts the investigation for alkaptonuria early in life.¹ Deposition of HGA in parenchymal organs can be problematic. Pigmented kidney, bladder, and prostate calculi often require surgical intervention. Calcification of cardiac valves results in valvular insufficiency or stenosis and may require

replacement. Coronary artery calcification is present in half of patients by the end of the sixth decade and is independent of serum cholesterol.¹ Pigment deposition has been found both intracellularly and intercellularly and can be granular or diffuse. Typically, large globules of yellow-brown pigment are deposited within collagen bundles. Pigment can also be observed within eccrine glands, elastic fibers, endothelial cells, and macrophages.⁴

Mutations in the HGD gene, located on chromosome 3q21-q23, can be investigated on a research basis.¹ However, the diagnosis of alkaptonuria relies on the detection of elevated HGA levels in the urine, as measured by gas chromatography-mass spectrometry or colorimetric acid analysis.⁵ In our setup these tests are not available; however, screening test for urine HGA, such as the urine ferric chloride test, followed by confirmation with ammoniac silver nitrate test can be used to establish the diagnosis in clinically suspected cases.⁶

Treatment options for alkaptonuria are directed at managing complications. Although many therapeutic approaches have been investigated, including high-dose vitamin C to enhance HGA degradation,⁷ none has been effective in reversing the primary defect. Dietary therapy restricting phenylalanine and tyrosine has no demonstrable clinical efficacy, and is difficult to maintain.² Nitisinone, approved for the treatment of tyrosinemia type I, is currently under investigation as a potential treatment. This compound, initially developed as an herbicide, inhibits 4-hydroxyphenylpyruvic dioxygenase, the enzyme that produces HGA it dramatically

reduced urine HGA levels in patients with alkaptonuria.⁸ Long term clinical trials are planned to determine the benefit of nitisinone in preventing joint deterioration and pain.

Other causes of blue pigment deposition include topical hydroquinone therapy (exogenous ochronosis) or carbolic acid dressings used for chronic ulcers, and systemic medications such as minocycline, amiodarone, and quinacrine. Minocycline-induced pigmentation has been observed with chronic use involving cumulative doses greater than 100g especially in patients with rheumatologic or dermatologic conditions.⁹

References

1. Phornphutkul C, Introne WJ, Perry MB et al. Natural history of alkaptonuria. *N Engl J Med* 2002; **347**: 2111-21.
2. La Du BN. Alkaptonuria. In: Scriver CR, Beaudet AL, Sly WS et al., editors. *The Metabolic and Molecular Bases of Inherited Disease, 8th edn*. New York: McGraw-Hill; 2001. p. 2109-23.
3. Smith JW. Ochronosis of the sclera and cornea complicating alkaptonuria: review of the literature and report of four cases. *JAMA* 1942; **120**: 1282-7.
4. Touart DM, Sau P. Cutaneous deposition diseases: part II. *J Am Acad Dermatol* 1998; **39**: 527-44.
5. Lustberg TJ, Schulman JD, Seegmiller JE. The preparation and identification of various adducts of oxidized homogentisic acid and the development of a new sensitive calorimetric assay for homogentisic acid. *Clin Chim Acta* 1971; **35**: 325-33.
6. Burtis CA, Ashwood ER, eds. *Tietz Textbook of Clinical Chemistry, 3rd edn*. Philadelphia: WB Saunders; 1998.
7. Sealock RR, Gladstone M, Steele JM. Administration of ascorbic acid to an alkaptonuric patient. *Proc Soc Exp Biol Med* 1940; **44**: 580-3.
8. Mitchell GA, Grompe M, Lambert M, Tanguay RM. Hypertyrosinemia. In: Scriver CR, Beaudet AL, Sly WS et al., eds. *The Metabolic and Molecular Bases of Inherited Disease, 8th edn*. New York: McGraw-Hill; 2001. p.1777-1805.
9. Eisen D, Hakin MD. Minocycline-induced pigmentation: incidence, prevention and management. *Drug Saf* 1998; **18**: 431-40.