

## Review Article

# Vitiligo: new etiology-based treatments

Abdul Hameed, Zahida Rani, Atif Hasnain Kazmi

Department of Dermatology, King Edward Medical College/ Mayo Hospital, Lahore

**Abstract** Vitiligo is an acquired depigmentary disorder characterized by a chronic and progressive loss of melanocytes from the epidermis. The etiopathogenesis of vitiligo is still not fully understood, and the major theories include melanocyte destruction (autoimmune, neural and impaired redox status) and melanocyte inhibition or defective adhesion. Recently a new theory, melanocytorrhagy, was forwarded. In this review are also discussed the new etiology-based treatments, mainly topical calcipotriol, topical immunomodulators and topical catalase.  
**Key words** vitiligo, calcipotriol, tacrolimus, pimecrolimus, catalase.

Vitiligo is an acquired depigmentary dermatosis characterized by sharply-demarcated lesions heterogeneous in size and shape. The disease generally runs a progressive course. The disease affects 1-2% of the world population, irrespective of age, sex, and skin color.<sup>1</sup>

From therapeutic and prognostic viewpoint, vitiligo is broadly classified in two major subtypes, segmental vitiligo (SV) including focal lesions confined to a segment of the body that does not progress towards generalized disease; and non-segmental vitiligo (NSV) which comprises all generalized usually symmetrical forms, including acrofacial vitiligo.<sup>1,2</sup>

Vitiligo is a very common disorder and a major cause of stigmatization and quality of life impairment especially in colour communities like ours. By many, vitiligo is considered only a cosmetic problem<sup>3</sup>; nonetheless, the quality of life studies indicate that the psychosocial problems are of the same magnitude as those found in

patients with psoriasis and eczema.<sup>4</sup> For the same reasons, vitiligo remains a growing therapeutic challenge for treating physicians

In vitiligo, especially, the NSV, there is progressive loss of melanocytes from the epidermis and follicular reservoir in some cases.<sup>2</sup> The etiology of vitiligo is still not fully elucidated. The major classical theories of vitiligo include melanocyte destruction (autoimmune, neural and impaired redox status), melanocyte inhibition or defective adhesion. Of late, a new theory proposed 'melanocytorrhagy' as the primary defect underlying this melanocyte loss.<sup>2</sup>

Although different therapeutic modalities are in vogue, still there remain unmet therapeutic needs. To address this question a few new etiology-based treatments have been launched over the last few years.

### Advances in pathophysiology

The basic defect in vitiligo is loss of melanocytes.<sup>5</sup> Then, the central question is: are melanocytes destroyed *in situ* in NSV or are they lost because of other mechanisms? Different old and new theories addressing this question are as follows.

---

#### Address for correspondence

Dr. Abdul Hameed,  
Department of Dermatology, Unit I,  
King Edward Medical College/Mayo  
Hospital, Lahore.  
E mail: hameed@mayoderm.org.pk

### **1. Theory of melanocyte destruction**

This is the most popular theory of vitiligo; nevertheless, melanocyte destruction has never been clearly demonstrated in vitiligo.<sup>2</sup> Theoretically, this melanocyte destruction can occur either by apoptosis or necrosis. The absence of conspicuous inflammatory infiltrate suggests apoptosis to be the major underlying pathway, as shown in animal studies.<sup>8</sup> However, melanocyte apoptosis has never been convincingly demonstrated in human skin. Furthermore, the intrinsic resistance of melanocytes to apoptosis is relatively high.<sup>9</sup> Melanocyte destruction can occur in different ways.

*A. The autoimmune theory of melanocyte destruction* Melanocytes in vitiligo are killed by autoimmune effector mechanisms, either cytotoxic T cells or autoantibodies directed to melanocyte surface antigens, as a result of loss of self-tolerance. This theory constitutes the basis of use of immunosuppressive drugs in vitiligo.<sup>2</sup> In response to some melanosomal antigens, an influx of Th1 lymphocytes is reported in the epidermis. These cells secrete TNF- $\alpha$  and other cytokines lethal to melanocytes.<sup>10</sup> Melanocyte-reactive cytotoxic T cells have been described in peripheral blood of vitiligo patients.<sup>11</sup>

*B. The neural theory of vitiligo* proposes that melanocytes are lost directly or indirectly by an inappropriate reaction of these (neural crest-derived) cells to neuropeptides, catecholamines or their metabolites, or more generally to an overactive sympathetic system.<sup>2</sup> It is supported by the evidence that vitiligo is commonly precipitated by stress. However, the concentration of catecholamines in vitiliginous skin is not

considered sufficient to kill melanocytes, and the time course of the production of catecholamines does not favour cause-effect relationship. However, a role of altered oxidative stress defenses has been speculated.<sup>12</sup> The generation of an excess of catecholamines produces oxidative products toxic for the melanocytes, providing basis for a mixed neural-autotoxic or biochemical hypothesis.<sup>13</sup>

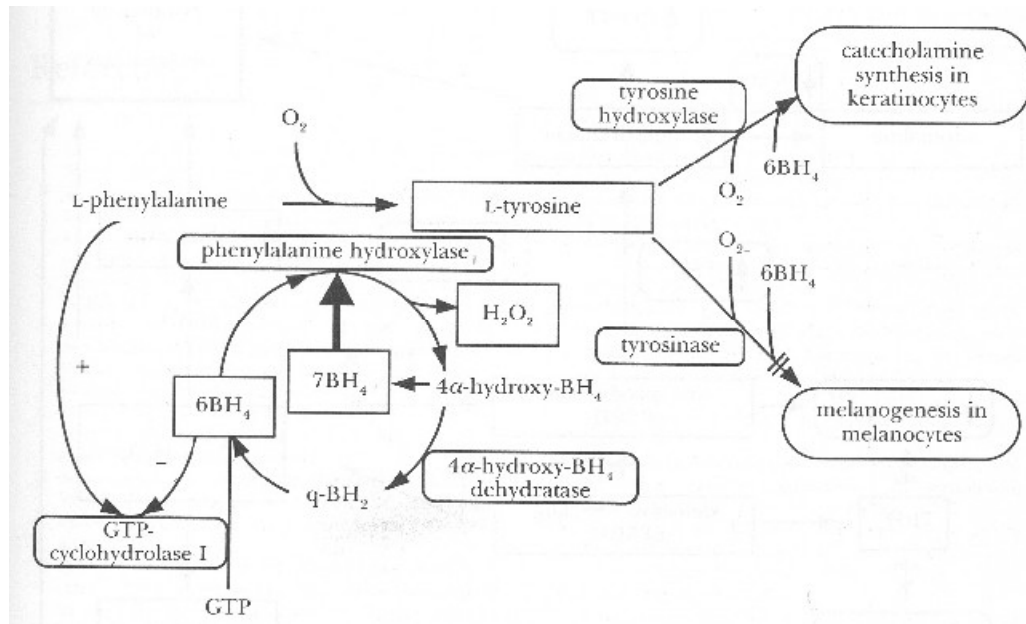
*C. The impaired redox status theory* states that vitiligo melanocyte death results from an intrinsic increased sensitivity to oxidative stress arising either from toxic intermediates of melanin precursors or from other sources.<sup>2</sup> Low catalase activity leading to epidermal accumulation of H<sub>2</sub>O<sub>2</sub> has been demonstrated in non-lesional and lesional NSV skin and in cultured melanocytes (**Figure 1**).<sup>14,15</sup>

Studies suggest that catalase helps to establish melanocytes cultures from NSV patients<sup>16</sup> or to reestablish their function after exposure to H<sub>2</sub>O<sub>2</sub>.<sup>16</sup> These data are used as basis for the use of oral and topical antioxidants in the treatment of NSV.

Increased intracellular calcium in melanocytes and keratinocytes could inhibit the activity of the antioxidant enzyme thioredoxin reductase.<sup>17</sup> This is sustaining the potential use of calcium modulators, such as calcipotriol in NSV.

### **2. The theories of melanocyte inhibition or defective adhesion**

According to this, the death of melanocytes is not essential for depigmentation in vitiligo, but speculate either a primary effect on inhibition of melanogenesis, or on the



**Figure 1** H<sub>2</sub>O<sub>2</sub> and its inhibitory effect on melanogenesis [16]

disappearance of melanocytes because of defective adhesion.<sup>2</sup> This is supported by following observations. First, the presence of residual melanocytes in the follicular reservoir give rise to repigmentation of vitiliginous patches after phototherapy.<sup>18</sup> Persistent melanocytes, showing an ectopic distribution of premelanosomes within keratinocytes of the suprabasal layers, have been observed in lesional skin of long standing vitiligo.<sup>19</sup>

It is proposed that vitiligo is a sequential two-stage disease.<sup>20</sup> In the first stage, tyrosinase activity decreases, while in the second stage this inhibition of melanisation induces the death of melanocytes. This was further confirmed by other investigators.<sup>21</sup> It has also been suggested that defective adhesion is involved in melanocyte loss in NSV.<sup>22</sup> An increased level of tenascin has been detected in the basal membrane and in the papillary dermis<sup>23</sup> suggesting that this extracellular matrix molecule inhibits adhesion of melanocytes to fibronectin and

thus might contribute to the loss of melanocytes in vitiligo. The detachment and transepidermal elimination of melanocytes following minor trauma is the cause of depigmentation occurring after Koebner phenomenon.<sup>7</sup>

### 3. Melanocytorrhagy: a newer concept in vitiligo [7]

This theory takes into account all the above mentioned data including melanocyte detachment and transepidermal elimination, neuro-biochemical and autoimmune hypothesis. It proposes that vitiligo is a primary melanocytorrhagy disorder with altered melanocyte responses to friction and possibly other types of stress, inducing their indolent attachment and subsequent transepidermal loss.<sup>7</sup> Further studies are needed to prove this.

Dendrites of melanocytes not only help in melanosomes transfer to the surrounding keratinocytes but also help melanocytes to

adhere to basal membrane.<sup>7</sup> Cultured vitiligo melanocytes show stubby dendrites.<sup>24</sup> Similarly, the addition of H<sub>2</sub>O<sub>2</sub> in established cultures of normal melanocytes induces a loss of dendricity and in some cases melanocyte detachment.<sup>25</sup> The increased release of catecholamines might be an aggravating factor of NSV. It is suggested that in adhesion-deficient NSV melanocytes, dendrites are lost in response to reactive oxygen species or by increased release of catecholamines and exaggerates transepidermal loss.<sup>2</sup>

Besides defective adhesion and dendritic loss, other abnormalities may lead to a decrease in frictional resistance of melanocytes in NSV and eventually to their detachment by mechanical or chemical injury.<sup>20</sup> In NSV non-lesional skin, a few hours after friction, melanocytes detach from the basement membrane and are surrounded by degenerated keratinocytes, which extracellular granular material deposits.<sup>7</sup> After their detachment, melanocytes were seen in a mid-spinous location as early as 8 hours after friction, and 24 hours later, some melanocytes reached the stratum corneum. During this epidermal migration, melanocytes are still incontinent.

There is now *in vivo* evidence for chronic melanocyte loss from the entire skin of NSV patients, indicating clearly that it is a generalized skin disorder.<sup>2</sup> There is limited but convincing evidence that segmental vitiligo also belongs to the same spectrum. The following scenario leading to the clinical disease can be proposed: if melanocyte loss is not very marked, the aspect of the skin remains unchanged, while in areas submitted to strong or continuous

frictions, such as the extremities or eyelids, a massive detachment and loss of melanocytes is more likely to occur, with the clinical vitiligo macules.

### **New etiology-based treatments**

Based on the advances observed in the understanding of the aetiology of vitiligo in the course of the 90's, several new, innovative and aetiology-based treatments were proposed for vitiligo.

#### ***1. Topical calcipotriol***

Calcipotriol is derived from 1-24-dihydroxy-vitamine D<sub>3</sub> and has the same mechanisms of action as other vitamin D derivatives, and these mechanisms involve both genomic and non-genomic pathways.<sup>21</sup> In regards to vitiligo, the non-genomic mechanism is involved. Vitamin D increases intracellular calcium concentration through hydrolysis of phosphatidyl inositol phosphate, leading to production of diacylglycerol and inositol triphosphate with subsequent release of intracellular calcium stores. The intracellular calcium concentration regulates a number of cellular functions including proliferation and differentiation, including melanocytes.

As a perturbed calcium homeostasis had been documented in the vitiliginous skin, calcipotriol can be used in this indication. Parsad *et al.*<sup>22</sup> were first to determine the efficacy of the combination of PUVA with topical calcipotriol in the treatment of vitiligo. The results were twice more effective with calcipotriol than with placebo. Many other studies corroborated the results of topical calcipotriol and PUVA in achieving earlier pigmentation with a lower cumulative UVA dosage.<sup>23,24,25</sup> On the contrary, it was asserted that topical

calcipotriol alone was not an effective treatment of vitiligo.<sup>26,27</sup> Baysal *et al.*<sup>26</sup> and Shahzad<sup>27</sup> reported the failure of combination of topical calcipotriol to PUVA treatment compared with PUVA treatment alone.

A combination of topical calcipotriol and corticosteroids demonstrated the effectiveness in repigmenting vitiligo, even in patients who were previous topical corticosteroids failures.<sup>28</sup> Yet, another study, using calcipotriol in combination with narrow-band UVB in the treatment of vitiligo, showed good results. However, the regimen was not as effective in generalized vitiligo.<sup>29</sup> While other researchers Ada *et al.*<sup>30</sup> and Hartman *et al.*<sup>31</sup> found no added advantage of calcipotriol.

Summarizing the available data, it appears that calcipotriol as a monotherapy cannot give consistent results, nonetheless it could be effective when used in association with PUVA or narrow-band UVB, but more investigations will be necessary as regards its real efficacy.

Side effects of topical calcipotriol are reported in 10-34% of cases. They are generally benign, most commonly irritation at the site of application.<sup>22-31</sup> They are transient and can be minimized or avoided by co-application of topical corticosteroids.<sup>32</sup> A few cases of allergic contact dermatitis have been reported.<sup>33,34</sup> The association of calcipotriol with phototherapy is complex. UVA may degrade calcipotriol<sup>35</sup> whereas the ointment and cream block UVB when applied less than two hours before irradiation; this effect may be due to the vehicle. Concomitant treatment with UVB does not appear to increase the irritation of

calcipotriol treatment.<sup>36</sup> However, photosensitivity has been reported with the use of this combination.<sup>37</sup>

Systemic side effects e.g. hypercalcemia are rare with topical use of calcipotriol at doses less than 100g/week.

### ***Topical immunomodulators: tacrolimus and pimecrolimus***

Considering the abnormalities in both humoral and cell-mediated immunity in vitiligo patients, the use of immunomodulating agents, such as corticosteroids and more recently macrolide immunomodulators i.e. tacrolimus and pimecrolimus has been documented in the treatment of vitiligo.<sup>38</sup>

Tacrolimus is a highly lipophilic macrolide lactone, which *in vitro* experiments proved to be a potent inhibitor of T-cells activation.<sup>39</sup> Tacrolimus blocks T-cells activation by inhibiting the initial signal relayed to the T-cells nucleus after antigen has bound to the T-cells receptor. One of the key intermediate molecules involved in this signal transduction process is a phosphatase called calcineurin. This inhibitory activity suppresses gene transcription and blocks production of a number of cytokines, including IL-2, IL-3, IL-4, IL-5, granulocyte-macrophage colony-stimulating factor (GM-CSF) and interferon (IFN)- $\gamma$ .<sup>51</sup> Pimecrolimus, an ascomycin macrolactan derivative, also selectively blocks T lymphocyte and mast cell inflammatory cytokine production. Both Th1 and Th2 type cytokines are blocked by pimecrolimus.<sup>40</sup>

Because of their mechanisms of action and properties, both tacrolimus and pimecrolimus ointments are used in the

treatment of various immune-mediated dermatoses including atopic dermatitis and psoriasis.

Regarding their use in vitiligo, Grimes *et al.*<sup>40</sup> were the first to report successful use of topical tacrolimus 1% ointment in vitiligo. Later on, the results were confirmed by many other prospective studies,<sup>41,42,43</sup> including children.<sup>42,43</sup> The best results were obtained on sun-exposed areas i.e. face, neck. Infrequent side-effects were pruritus or burning following application of the drug. In a randomized, double-blind trial aimed to assess the safety and efficacy of topical 0.1% tacrolimus vs. 0.05% clobetasol.<sup>44</sup> Tacrolimus was proved to be almost as effective (82%) as clobetasol (98%) to restore skin color in lesions of vitiligo in children, with a few side-effects. Topical treatment with tacrolimus is associated with suppression of TNF- $\alpha$  in the treated skin, which could at least partially explain these results.<sup>40</sup>

Two studies combining 308 nm excimer laser with 0.1% tacrolimus ointment showed 50% and 70% improvement, respectively after 10 weeks period.<sup>45,46</sup> In both studies, topical tacrolimus was shown to enhance and fasten the results obtained with 308-nm excimer laser alone. Tolerance was excellent in both studies.

Paradoxically, there are few reports about the use of topical pimecrolimus in vitiligo. Topical pimecrolimus was shown to have a similar efficacy to 0.05% clobetasol in treatment of limited areas of vitiligo in the a small series of patients.<sup>47</sup>

Immediate side-effects of tacrolimus and pimecrolimus are pruritus and burning

sensation on application. Atrophy and other adverse effect of topical corticosteroids are not seen.<sup>40-47</sup> However, one case of focal hypertrichosis was reported during topical tacrolimus therapy for childhood vitiligo.<sup>48</sup> Considering the carcinogenic potential of topical tacrolimus and pimecrolimus, FDA recommends their use only as second-line agents for short term and intermittent treatment. The drugs should be avoided in children younger than 2 years of age.<sup>49</sup>

### **Topical catalase**

Use of topical catalase in vitiligo is based on the *ex vivo* studies showing that catalase helps to establish melanocyte cultures from NSV patients<sup>16</sup> or to reestablish their function after exposure to H<sub>2</sub>O<sub>2</sub>.<sup>16</sup>

The first clinical study<sup>16</sup> was conducted over a 36-month period in 33 patients with vitiligo. Patients applied a combination of a pseudocatalase and calcium chloride twice daily. A total-body exposure to suberythemogenic UVB was done twice weekly. Excellent repigmentation was reported to occur in the majority of the cases after 2-4 months, especially on the face and the dorsum of the hands. Focal vitiligo showed 90-100% repigmentation in all cases; whereas segmental vitiligo responded partially but was extremely slow in response. In the vulgaris type, good to moderate responses have been observed, but no repigmentation occurred on fingers and feet.

However, the results could not be testified subsequently. A recent study<sup>50</sup> designed to assess the efficacy of topical pseudocatalase mousse applied twice daily to the hand and face of vitiligo patients, in combination with twice weekly suberythemogenic narrow-

band UVB phototherapy did not show clear evidence of the efficacy of this regime, and was even demonstrating a slight tendency overall to worsening of the disease.

Of late, a new topical product (ViTiX®) containing a combination of vegetal catalase and superoxide dismutase has been used in vitiligo.<sup>52</sup> *In vitro* studies had previously demonstrated the capacity of a SOD + catalase complex to dramatically reduce the production of free radicals in vitiligo cell<sup>53</sup> and even to restore a normal level of melanin in melanocytes of vitiligo.<sup>54</sup> This latter result may likely be linked to the *in vivo* repigmenting effect of topical tacrolimus, associated to the suppression of TNF- $\alpha$  in the treated skin as both catalase and SOD.<sup>53</sup> were shown to drastically reduce the levels of TNF- $\alpha$  and other proinflammatory cytokines *in vitro* and *in vivo*.

A double-blind, controlled and randomized study<sup>51</sup> compared selective UVB phototherapy combined to either ViTiX® or an excipient in patients presenting with bilateral vitiligo of the limbs and trunk for more than 3 months. This study lasted for 6 months with twice-weekly phototherapy. The combination of SOD+catalase and selective UVB phototherapy showed 60% repigmentation as compared to 39% in selective UVB phototherapy alone group. Furthermore, the tolerance of this treatment was quoted as excellent.

### Conclusion

The last a few years have been very promising as regards the understanding of etiopathogenesis of vitiligo. Similarly, many newer treatments, based on the newer

concepts, have been added to the therapeutic arsenal of vitiligo.

### References

1. Bleehen SS, Anstey AV. Disorders of skin colour. In: Burns T, Breathnach S, Cox N, Griffiths C, eds. *Rook's Textbook of Dermatology*, 7<sup>th</sup> edn. Oxford: Blackwell Science; 2004. p. 39.1-39.68.
2. Gauthier Y, Cario-Andre M, Taieb A. A critical appraisal of vitiligo etiologic theories. Is melanocyte loss a melanocytorrhagy? *Pigment Cell Res* 2004; **16**: 322-32.
3. Porter J, Hill-Beuf A, Lerner A, Nordlund J. Response to cosmetic disfigurement: patients with vitiligo. *Cutis* 1987; **39**: 493-4.
4. Noor SM, Khurshid K, Mahmood T, Haroon TS. Quality of life in vitiligo patients. *J Pak Assoc Dermatol* 2004; **14**: 55-8.
5. Grimes PE. New insights and new therapies in vitiligo. *JAMA* 2005 ; **293**: 730-5.
6. Wang X, Erf GF. Apoptosis in feathers of Smyth line chickens with autoimmune vitiligo. *J Autoimmun* 2004; **22**: 21-30.
7. Gauthier Y, Cario-Andre M, Lepreux S *et al*. Melanocyte detachment after skin friction in non lesional skin of patients with generalized vitiligo. *Br J Dermatol* 2003; **148**: 95-101.
8. Wang X, Erf GF. Apoptosis in feathers of Smyth line chickens with autoimmune vitiligo. *J Autoimmun* 2004; **22**: 21-30.
9. Bowen AR, Hanks AN, Allen SM *et al*. Apoptosis regulators and responses in human melanocytic and keratinocytic cells. *J Invest Dermatol* 2003; **100**: 48-55.
10. Le Poole IC, Wankowicz-Kalinska A, van den Wijngaard RM *et al*. Autoimmune aspects of depigmentation in vitiligo. *J Investig Dermatol Symp Proc* 2004 ; **9**: 68-72.
11. Wankowicz-Kalinska A, van den Wijngaard RM, Tigges BJ *et al*. Immunopolarization of CD4+ and CD8+ T cells to Type-1-like is

- associated with melanocyte loss in human vitiligo. *Lab Invest* 2003; **83**: 683-95.
12. Cucchi ML, Frattini P, Santagostino G *et al*. Catecholamines increase in the urine of non-segmental vitiligo especially during its active phases. *Pigment Cell Res* 2003; **16**: 111-6.
  13. Morrone A, Piccardo M, de Luca C *et al*. Catecholamines and vitiligo. *Pigment Cell Res* 1992; **5**: 65-9.
  14. Goth L, Rass P, Pay A. Catalase enzyme mutations and their association with diseases. *Mol Diagn* 2004; **8**: 141-9.
  15. Hasse S, Gibbons NC, Rokos H. Perturbed 6-tetrahydrobiopterin recycling via decreased dihydropteridine reductase in vitiligo: more evidence for H<sub>2</sub>O<sub>2</sub> stress. *J Invest Dermatol* 2004; **122**: 307-13.
  16. Schallreuter KU, Wood JM, Lemke KR, Levenig C. Treatment of vitiligo with a topical application of pseudocatalase and calcium in combination with short-term UVB-exposure: a case study on 33 patients. *Dermatology* 1995; **190**: 223-9.
  17. Schallreuter KU, Pittelkow MP. Defective calcium uptake in keratinocytes cell cultures from vitiligo skin. *Arch Dermatol Res* 1988; **280**: 137-9.
  18. Tobin DJ, Swanson NN, Pittelkow MR *et al*. Melanocytes are not absent in lesional skin of long duration vitiligo. *J Pathol* 2000; **191**: 407-16.
  19. Morelli JG, Yohn JJ, Zekman T, Norris DA. Melanocyte movement *in vitro*: role of matrix protein and integrin receptors. *J Invest Dermatol* 1993; **101**: 605-8.
  20. Jimbow K, Chen H, Park JS, Thomas PD. Increased sensitivity of melanocytes to oxidative stress and abnormal expression of tyrosinase-related protein in vitiligo. *Br J Dermatol* 2001; **144**: 55-65.
  21. Guilhou JI. Calcipotriol. *Ann Dermatol* 2001; **128**: 229-37.
  22. Parsad D, Saini R, Vema N. Combination of PUVASOL and topical calcipotriol in vitiligo. *Dermc* 258 1998; **197**: 167-70.
  23. Ameen M, Exarchou V, Chu AC. Topical calcipotriol as monotherapy and in combination with psoralen plus ultraviolet A in the treatment of vitiligo. *Br J Dermatol* 2001; **145**: 476-9.
  24. Ermis O, Alpsoy E, Cetin L, Yilmaz E. Is the efficacy of psoralen plus ultraviolet A therapy for vitiligo enhanced by concurrent topical calcipotriol? A placebo-controlled double-blind study. *Br J Dermatol* 2001; **145**: 472-5.
  25. Chiaverini C, Passeron T, Ortonne JP. Treatment of vitiligo by topical calcipotriol. *J Eur Acad Dermatol* 2002; **16**: 137-8.
  26. Baysal V, Yildirim M, Erel A, Kesici D. Is the combination of Calcipotriol and PUVA effective in vitiligo? *J Eur Acad Dermatol Venereol* 2003; **17**: 299-302.
  27. Shahzad A. *Topical Calcipotriol alone vs. oral PUVA and topical Calcipotriol in the treatment of vitiligo* (Dissertation for fellowship). Karachi: College of Physicians and Surgeons Pakistan; 2003.
  28. Travis LB, Silverberg NB. Calcipotriene and corticosteroid combination therapy for vitiligo. *Pediatr Dermatol* 2004; **21**: 495-8.
  29. Kullavanijaya P, Lim HW. Topical calcipotriol and narrow-band ultraviolet B in the treatment of vitiligo. *Photodermatol Photoimmunol Photomed* 2004; **20**: 248-51.
  30. Ada S, Sabin S, Boztepe G *et al*. No additional effect of topical calcipotriol on narrow-band UVB phototherapy in patients with generalized vitiligo. *Photodermatol Photoimmunol Photomed* 2005; **21**: 79-83.
  31. Hartmann A, Lurz C, Hamm H *et al*. Narrow-band UVB311 nm vs. broad-band UVB therapy in combination with topical calcipotriol vs. placebo in vitiligo. *Int J Dermatol* 2005; **44**: 736-42.
  32. Bruynzeel DP, Hol CW, Nieboer C. Allergic contact dermatitis to calcipotriol. *Br J Dermatol* 1992; **127**: 66.
  33. Molin L. Contact dermatitis after calcipotriol and patch test evaluation. *Acta Derm Venereol* 1996; **76**: 163-4.
  34. Kragballe K, Barnes L, Hamberg KJ *et al*. Calcipotriol cream with or without concurrent topical corticosteroid in

- psoriasis: tolerability and efficacy. *Br J Dermatol* 1998; **139**: 649-54.
35. Lebwohl M, Hecker D, Martinez J *et al*. Interaction between calcipotriol and ultraviolet light. *J Am Acad Dermatol* 1997; **37**: 93-5.
  36. Molin L and the Calcipotriol-UVB study group. Does addition of topical calcipotriol to UVB increase the risk of irritant reactions in psoriasis? *Acta Derm Venereol* 1997; **77**: 401-2.
  37. McKenna KE, Stems RS. Photosensitivity associated with combined UVB and calcipotriene therapy. *Arch Dermatol* 1995; **131**: 1305-7.
  38. Kostovic K, Pasic A. New treatment modalities for vitiligo: focus on topical immunomodulators. *Drugs* 2005; **65**: 447-59.
  39. Tocci MJ, Matkovich DA, Collier KA *et al*. The immunosuppressant FK-506 inhibits expression of early T-cell activation genes. *J Immunol* 1989; **143**: 718-26.
  40. Grimes PE, Morris R, Avannis-Aghajani E *et al*. Topical tacrolimus therapy for vitiligo: therapeutic responses and skin messenger RNA expression of proinflammatory cytokines. *J Am Acad Dermatol* 2004 ; **51**: 52-61.
  41. Tanghetti EA. Tacrolimus ointment 0.1% produces repigmentation in patients with vitiligo: results of a prospective patients series 259 003; **71**: 158-62.
  42. Silverberg NB, Lin P, Travis L *et al*. Tacrolimus ointment promotes repigmentation of vitiligo in children: a review of 57 cases. *J Am Acad Dermatol* 2004; **51**: 760-6.
  43. Kanwar AJ, Dogra S, Parsad D. Topical Tacrolimus for treatment of childhood vitiligo in Asians. *Clin Exp Dermatol* 2004; **29**: 589-92.
  44. Lepe V, Moncada B, Castanedo-Cazares JP *et al*. A double-blind randomized trial of 0.1 % tacrolimus vs 0.05% clobetasol for the treatment of childhood vitiligo. *Arch Dermatol* 2003; **139**: 581-5.
  45. Kawalek AZ, Spencer JM, Phelps RG. Combined excimer laser and topical tacrolimus for the treatment of vitiligo: a pilot study. *Dermatol Surg* 2004; **30**: 130-5.
  46. Passeron T, Ostovari N, Zakaria W *et al*. Topical tacrolimus and the 308-nm excimer laser: a synergistic combination for the treatment of vitiligo. *Arch Dermatol* 2004; **140**: 1065-9.
  47. Coskun B, Saral Y, Turgut D. Topical 0.05% clobetasol propionate vs. 1% pimecrolimus ointment in vitiligo. *Eur J Dermatol* 2005; **15**: 88-91.
  48. Prats Caelles I, Herranz Pinto P, de Ayala Casado EL, de Lucas Laguna R. Focal hypertrichosis during topical tacrolimus therapy for childhood vitiligo. *Pediatr Dermatol* 2005; **22**: 86-7.
  49. FDA Public Health Advisory. Elidel (Pimecrolimus) cream and Protopic (Tacrolimus) ointment. March 10, 2005.
  50. Patel DC, Evans A V, Hawk JLM. Topical pseudocatalase mousse and narrowband UVB phototherapy is not effective for vitiligo: an open, single-centre study. *Clin Exp Dermatol* 2002; **27**: 641-4.
  51. Khemis A, Ortonne IP. Study comparing a vegetal extract with superoxide dismutase and catalase activities (ViTiX®) plus selective UVB phototherapy versus an excipient plus selective UVB phototherapy in the treatment of vitiligo vulgaris. *Nouv Dermatol* 2004; **23**: 2-3.
  52. Zhang Y, Wang JZ, Wu YJ, Li WG. Anti-inflammatory effect of recombinant human superoxide dismutase in rats and mice and its mechanism. *Acta Pharmacol Sin* 2002; **23**: 439-44.
  53. Chang SC, Kao MC, Fu MT, Lin, CT. Modulation of NO and cytokines in microglial cells by Cu/Zn superoxide dismutase. *Free Radic Biol Med* 2001; **31**: 1084-9.
  54. Lange RW, Germolic DR, Foley JF, Luster MI. Antioxidants attenuate anthralin-induced skin inflammation in BALB/c mice: role of specific Pro inflammatory cytokines. *J Leukoc Biol* 1998; **64**: 170-6.



This document was created with Win2PDF available at <http://www.daneprairie.com>.  
The unregistered version of Win2PDF is for evaluation or non-commercial use only.